AD_____

Award Number: DAMD17-03-1-0109

TITLE: Telemedicine Based Ultrasound for Detecting Neonatal Heart Disease in Babies at Remote Military or Native American Health Care Facilities

PRINCIPAL INVESTIGATOR: David J. Sahn, M.D.

CONTRACTING ORGANIZATION: Oregon health Sciences University
Portland, Oregon 97239-3098

REPORT DATE: March 2004

TYPE OF REPORT: Annual

PREPARED FOR: U.S. Army Medical Research and Materiel Command
Fort Detrick, Maryland 21702-5012

DISTRIBUTION STATEMENT: Approved for Public Release;
Distribution Unlimited

The views, opinions and/or findings contained in this report are those of the author(s) and should not be construed as an official Department of the Army position, policy or decision unless so designated by other documentation.

BEST AVAILABLE COPY

20040907 075

REPORT DOCUMENTATION PAGE

Form Approved
OMB No. 074-0188

Public reporting burden for this collection of information is estimated to average 1 hour per response, including the time for reviewing instructions, searching existing data sources, gathering and maintaining the data needed, and completing and reviewing this collection of information. Send comments regarding this burden estimate or any other aspect of this collection of information, including suggestions for reducing this burden to Washington Headquarters Services, Directorate for Information Operations and Reports, 1215 Jefferson Davis Highway, Suite 1204, Arlington, VA 22202-4302, and to the Office of Management and Budget, Paperwork Reduction Project (0704-0188), Washington, DC 20503

1. AGENCY USE ONLY (Leave blank)	2. REPORT DATE	3. REPORT TYPE AND DATES COVERED
	March 2004	Annual (15 Feb 2003 - 14 Feb 2004)

4. TITLE AND SUBTITLE
Telemedicine Based Ultrasound for Detecting Neonatal Heart Disease in Babies at Remote Military or Native American Health Care Facilities

5. FUNDING NUMBERS
DAMD17-03-1-0109

6. AUTHOR(S)
David J. Sahn, M.D.

7. PERFORMING ORGANIZATION NAME(S) AND ADDRESS(ES)
Oregon Health Sciences University
Portland, Oregon 97239-3098

E-Mail: sahnd@ohsu.edu

8. PERFORMING ORGANIZATION REPORT NUMBER

9. SPONSORING / MONITORING AGENCY NAME(S) AND ADDRESS(ES)
U.S. Army Medical Research and Materiel Command
Fort Detrick, Maryland 21702-5012

10. SPONSORING / MONITORING AGENCY REPORT NUMBER

11. SUPPLEMENTARY NOTES
Original contains color plates: All DTIC reproductions will be in black and white.

12a. DISTRIBUTION / AVAILABILITY STATEMENT
Approved for Public Release; Distribution Unlimited

12b. DISTRIBUTION CODE

13. ABSTRACT (Maximum 200 Words)

Our partnership of investigators from Madigan Army Medical Center at Fort Lewis, Washington, and Oregon Health Sciences University in Portland, will test the hypothesis that trained primary care practitioners or nurses can, with telemedicine supervision, perform cardiac ultrasound exams on neonates at risk for heart disease, and thereby impact time to diagnosis and outcomes. This study is targeted at Military Medical Facilities within Region 11, and Western Regional Medial Command. It will include two large Alaska Native Health Care Centers. Echocardiography has had major impact in the management of neonates suspected of having congenital heart disease. The expensive, specialized equipment and significant expertise to adequately perform and interpret these studies usually is present only in tertiary level medical centers with a pediatric cardiologist on staff. Initial results of a National Multicenter Neonatal Telemedicine Echo Outcomes Study, developed by the Principal Investigator, suggest that telemedicine-implemented diagnosis positively affects outcomes in infants suspected of having congenital heart disease. As an added impact of our program, we will develop expertise within caregivers who have previously not been able to perform these necessary exams, and will integrate the use of low-cost, yet high-performance hand-held ultrasound scanners, so as to provide the participating centers with new diagnostic health care capabilities.

14. SUBJECT TERMS
Echocardiography, ultrasound, telemedicine, neonates, congenital heart disease, outcomes

15. NUMBER OF PAGES
54

16. PRICE CODE

17. SECURITY CLASSIFICATION OF REPORT	18. SECURITY CLASSIFICATION OF THIS PAGE	19. SECURITY CLASSIFICATION OF ABSTRACT	20. LIMITATION OF ABSTRACT
Unclassified	Unclassified	Unclassified	Unlimited

Table of Contents

Cover	**1**
SF 298	**2**
Table of Contents	**3**
Introduction	**4**
Progress Report	**4**
Key Research Accomplishments	**11**
Reportable Outcomes	**11**
Conclusions	**11**
References	**11**
Appendices	**12**
Appendix A. Reference 1	**13**
Appendix B. Abstract, Reference 2	**21**
Appendix C. Anatomical Drawings from Reference 3	**22**
Appendix D. Essentials of Echocardiography #4	**27**
Appendix E. Slides Used for Course "Anatomic Basis of Echocardiography	**33**
Appendix F. Sample Data Entry Pages for DOD Infant Heart Study	**45**

Introduction

This impact and outcomes research proposal will specifically test the hypothesis that a method for reliable and rapid assessment of newborn infants at risk for heart disease can be developed for telediagnosis using a small hand-held ultrasound system, with an appropriate high frequency transducer. The unique setting of the examination will be that it the health professional performing the examination may not be a cardiologist or a fully trained echocardiographer but the examination will be monitored, supervised and guided using telemedicine links, which will also allow control of scanning system settings by the remote supervisor, who is an expert Pediatric Cardiologist/echocardiographer. The study should set precedents in expanding the pool of personnel who can perform echocardiography in these facilities, and help define the clinical applications of low-cost, high-performance ultrasound systems.

The program will assess diagnostic accuracy as the primary outcome variable and time to diagnosis, incidence of unnecessary transport and length of stay during initial hospitalization including transfer when it occurs as secondary medical outcomes. Diagnosis will be established by testing at a referral center or examination and ultrasound performed by the expert consultant on a follow-up visit occurring at the referral site. In addition to any diagnostic findings of significance that are missed, we will survey and document adverse events in the patient's subsequent course, both medical and social, e.g. parent/baby separation, parental anxiety. Each infant will be followed for 3 months from the time of the initial diagnosis encounter and will be compared to historical controls. Finally, our study will also include a financial outcomes/cost analysis.

Progress Report

Shortly after the funding of this proposal, a number of the military personnel at the outreach sites, and those assisting us at Madigan Army Medical Center, had a change of assignment. Many of them were away until late June or July, and gradually came back, becoming available by the middle of summer.

To date our study has finalized the list of participating centers, which include 6 military hospitals in the Pacific Northwest and Alaska, and 2 Alaska Native health centers in Bethel and Anchorage. The participating individuals changed significantly during the spring of 2003 and contact needed to be reestablished during the summer.

The latest Contacts list is shown below.

NAME (Title/Rank)	Company	Position	Email
Kyle, Brittney (Mr.)	3rd Med Group	IMD	brittney.kyle@elmendorf.af.mil
Callum, Heather (MAJ)	3rd Med Group	Chief of Peds	heather.callum@elmendorf.af.mil
Choate, Nicola (MAJ)	3rd Med Group	(Acting) Chief of Peds	nicola.choarte@elmendorf.af.mil
Bunger, Tom (Mr.)	Alaska Native Tribal Health Consortium	Wide Area Network Manager	tbunger@afhcan.org
Gonzales, Calle (Dr.)	ANMC	Medical Director of PICU	cgonzales@anmc.org
Engel, Michael (Dr.)	ANMC	Pediatrician	mcengel@anmc.org
East, Tom (Mr.)	ANMC	IT	teast@anmc.org
Snyder, David (Dr.)	ANMC	Hospital Director	dasnyder@anmc.org
Shankle, Bob (Mr.)	BACH	Chief IMD	Bob.Shankle@nw.amedd.army.mil
Tullberg, Julie (MAJ)	BACH	Chief of Peds	Julie.Tullberg@nw.amedd.army.mil

NAME (Title/Rank)	Company	Position	Email
Bolton, Karl (MAJ)	BACH	Chief, Clinical Services	Karl.Bolton@nw.amedd.army.mil
Cherry, Robyn (CW2	BACH	Chief of Medical Maintenance	Robyn.Cherry@nw.amedd.army.mil
Spieker, Michael (CPT)	BMC	Family Practice	m.spieker@pnw.med.navy.mil
Corser, Donna (Ms.)	BMC	IMD	DCorser@pnw.med.navy.mil
O'Malley, Peter (LCDR)	BMC	Pediatrician	omalleyp@pnw.med.navy.mil
Foltz, Talitha (Petty Officer (HM3))	BMC	Dep of Peds	foltzt@pnw.med.navy.mil
Roberts, William (CPT)	BMC	Hospital Commander	RobertsW@pnw.med.navy.mil
Andersen, Karie (CDR)	BMC	Chief of Peds	andersenk@pnw.med.navy.mil
Donalty, Andrea (LCDR)	NHOH	Chief of Peds	abdonalty@nhoh.med.navy.mil
Wolniakowski, Dan (Mr.)	NHOH	Chief IMD	drwolniakowski@nhoh.med.navy.mil
Shipley, Amy (LT)	NHOH	Pediatrician	aashipley@nhoh.med.navy.mil
Ralston, Mark (CPT)	NHOH	Pediatrician (As of 08/04)	N/A
Herrold, Susan (CPT)	NHOH	Hospital Commander	sbherrold@nhoh.med.navy.mil
Nelson, Brent (COL)	WACH	DCCS	Brent.Nelson@nw.amedd.army.mil
Williams, Calvin (COL)	WACH	Hospital Commander	Calvin.Williams@nw.amedd.army.mil
Stoyas, Athena (CPT)	WACH	Pediatrician	Athena.Stoyas@nw.amedd.army.mil
Warner, Robert (CPT)	WACH	Chief of Peds	Robert.Warner@nw.amedd.army.mil
Kinyon, Raymond (Mr.)	WACH	IMD	Raymond.Kinyon@nw.amedd.army.mil
Rogers, Skip (Mr.)	WACH	IMD	Skip.Rogers@nw.amedd.army.mil
Berard, Eric (CPT)	WACH	Chief IMD	Eric.Berard@nw.amedd.army.mil
Ward, Laura (MAJ)	WACH	IMD	Laura.Ward1@nw.amedd.army.mil
Klejka, Joe (Dr.)	YKHC	Medical Director	joe_klejka@ykhc.org
Warzewick, Valerie (Ms.)	YKHC	IT	Val_Warzewick@ykhc.org
DeLeon, Jenni (Dr.)	YKHC	Service Chief, Pediatric Dep.	Jenni_Deleon@ykhc.org
Wells, Ronald (CPT)	MEDDAC-AK	Pediatrician	Ronald.Wells@nw.amedd.army.mil
Harder, Scott (SFC)	MEDDAC-AK	Logistics	Scott.Harder@nw.amedd.army.mil
Mace, Phil (Mr.)	MEDDAC-AK	IMD	Phil.Mace@nw.amedd.army.mil
Hendrix, Mary Alice (Ms.)	MEDDAC-AK	Logistics	MaryAlice.Hendrix@nw.amedd.army.mil

After finalization of the network plan and the reestablishment of contacts at the outreach sites, dialogue began with IT network personnel about the availability of fast fiber communications links and issues related to available bandwidth and potential firewalls, especially for the military installations.

A survey of telecommunication infrastructure has been completed; Polycom units have been purchased and are ready for distribution; IT contacts at each facility have been made, and individualized installation plans have been developed.

Contacts were also developed at the two hospitals that will supply concurrent controls and the IRB process has begun. Blanchfield Army Hospital in Fort Campbell, Kentucky (Robert Moore) and Bayne-Jones Army Community Hospital at Fort Polk in Leesville, Louisiana (CPT Joseph Gramling).

SonoHeart scanners have been ordered for the network and have been delivered to Madigan Army Medical Center. Those at OHSU and at MAMC are in use. Application of the SonoHeart by our group at OHSU in a blinded diagnostic study was reported in the Journal of

the American Society of Echocardiography (1). A PDF copy of the paper is appended (Appendix A).

The study showed substantial diagnostic accuracy, especially in neonatal examinations, which forms the basis for the type of results we should expect in telemedicine application.

Additionally, Leo Catallo of SonoSite has completed the remote control capability software package that uses a PC computer to control trackball functions on a remote scanner and can be utilized in conjunction with Polycom FX or 512 systems (2). A copy of the abstract is appended (Appendix B). The system has been tested and is ready for final software debugging. A final test through the Polycom units will be undertaken between MAMC and OHSU.

Infrastructure Report

Introduction

This document provides a general overview the equipment requirements, information regarding connecting the eight sites, and a list of questions that should be addressed. In the future, this lengthy email will not be necessary. Within the next week, the MAMC Informatics Department should have received approval to provide access for our project to Microsoft Project program. This system will allow me to send you timeline updates and reminders regarding upcoming deadlines.

Connection Options

The current circumstances present us with a situation where each site must be addressed individually. There is no overarching body that can present us with the installation and approval per hospital to set up this equipment. Even if we are to use solely military lines, each facility must address their network connectivity issues, hospital approval, and military approval per line. Below is an overview of what information we presently have. There are still gaps in this information.

The simplest method to connect the Polycom ViewStation 512 to the Polycom FX at MAMC is through 3 BRI ISDN lines (384kbps). However, when we use an already established T-1 line, and sequester six channels from this line, a V.35 connection is needed in order to connect the Polycom 512 to MAMC. The Polycom FX is best used with a PRI T-1 line. This will permit four 384 kbps calls to be bridged for simultaneous review.

1. **ANMC:** The original intent was to utilize the existing line infrastructure that was established for a telemedicine program at ANMC and Bethel. By sequestering bandwidth from the existing lines, the Polycom 512 at each facility would function as if it were functioning on 3 ISDN lines (384kbps). Currently, concern has been expressed regarding the capabilities of doing any connection with ANMC. MAMC Informatics staff will be in touch with them and discuss the possibilities.
2. **Bethel:** As mentioned above, the original intent was to use existing lines. I have contacted Valerie Warzewick, the hospital's IT person, and hope to get to speak with her within the next few days. There may be some issues about pulling too much from their T-1 line, as that is their only line into the area. However, they seem to be prepared to assist us. There have also been some concerns expressed by MAMC staff about connecting a non-military facility with a military facility, particularly if we use military lines at any point in the connection.
3. **BACH:** Private ISDN lines are probably going to be the most effective method of connection with BACH. There is a single T-1 line that travels between BACH and MAMC, but this is a MEDNET line. This handles all traffic - Internet, PACS, email, etc.

We can still consider the possibility of using MEDNET, however this has not been advised. The suggestion was made that DISA (Defense Information Systems Agency) could increase the bandwidth and dedicate the extra bandwidth to the TeleEcho project. However, most likely, they would want the grant to fund it, and we would have to contend with a number of network connectivity issues (AR 25-2, DITSCAP). DITSCAP (DoD Information Technology Security Certification and Accreditation Process) applies to the acquisition, operation and sustainment of any DoD system that collects, stores, transmits, or processes unclassified or classified information within military facilities. BACH is also preparing a transition to a new hospital, which may or may not effect what can be accomplished at this point-and-time.

4. **Elmendorf:** It has been suggested that segments of a lines between Fairbanks and Anchorage, Anchorage and Ft. Lewis can be utilized. These lines would be seized at a T1 bandwidth to serve the MAMC Polycom FX; therefore, a V.35 connection would be needed for the Polycom 512. I am assuming that these lines are MEDNET as well, as that was the case for BACH. Something that has been a problem for other projects were Elmendorf's firewalls. If COL David William, the Informatics point-of-contact for this grant as it as it was written, knew that the firewalls were not going to be a problem, then he left no indication of that, nor did he address future changes in firewall technology. A future complication that may arise with Elmendorf is they are currently re-networking the hospital to be the same standards of the rest of the military base. This may mean further problems with firewalls.
5. **Whidbey:** If we choose to use commercial lines with Whidbey, we have only one choice of phone company - Whidbey Net. Once I receive more information from their point-of-contact, we will be able to evaluate the situation with Whidbey better.
6. **Bremerton:** As of yet, we have not received enough information to evaluate Bremerton. We do know that MAMC already has a commercial T-1 line linking to Bremerton for another project. In order to set this up they had to pay $2000 per month to the phone company and $2000 to DISA (Defense Systems Information Agency).
7. **Ft. Irwin:** Though Weed has numerous issues, most likely they are going to be one of the simplest to connect to MAMC. They have a strong Informatics Department that can work closely with MAMC. Furthermore, as an Army facility they are under General Dunn's direct command and closely linked to MAMC already.
8. **OHSU:** OHSU is on T1 connections; however, how OHSU will be connected to MAMC has not yet been determined.

Both AT&T and Qwest are willing to assist us in this project. Though this does cost, it is not excessive. AT&T is preparing a proposal using information I provided regarding the requirements and the sites. Based upon their Internet pricing, the total should not be too high. Qwest appears to be the more affordable of the two, but has a smaller coverage area. They are able to provide ISDN service for $69.10 per month, with an $83.00 set up fee. These are just their basic figures, so it may be more. However, it gives the impression that for some sites this is a feasible figure. Furthermore, they are willing to setup the lines within two weeks of notification.

A detailed document has been developed outlining the communications infrastructure and issues related to installing Polycom systems. It is possible that some outlay for purchase of lines structured by the grant group may be required. It had been hoped that all line infrastructure would be provided by military or federal agencies; but the sequestered bandwidth and HIPAA

compliance level that we require may entail at least one commercial T1 pipeline from Alaska to MAMC. The plan for Alaska would then be to bring the T1 infrastructure from Bethel, Anchorage, Elmandorf and Fairbanks together at the AFHCAN telemedicine office where Tom Bunger, the wide area manager for the Alaska Federal Health Care Access Network of the Alaska Native Tribal Healthcare Consortium will lead. Transfer of data will be facilitated from this central location.

Human Subjects Approval Process

Protocol Number: 203046 *Status:* Approved
Protocol Title: Telemedicine Based Ultrasound for Detecting Neonatal Heart Disease in Babies at Remote Military or Native American Health Care Facilities
Principal Investigator: Puntel RA (LTC Robert A. Puntel, MC)
Dept: Pediatrics
Objective: This impact and outcomes research proposal will specifically test the hypothesis that a method for reliable and rapid assessment of newborn infants at risk for heart disease can be developed for tele-diagnosis using a small hand-held ultrasound system with an appropriate high frequency transducer. The unique setting will be that the healthcare professional performing the examination may not be a cardiologist or a fully trained echocardiographer, but the examination will be monitored, supervised and guided using telemedicine links that will also allow control of the scanning system settings by the remote supervisor who is an expert Pediatric Cardiologist/echocardiographer. The program will assess diagnostic accuracy as the primary outcome variable and time to diagnosis, incidence of unnecessary transport and length of stay during initial hospitalization including transfer when it occurs, as secondary medical outcomes. Diagnosis will be established by testing at a referral center or examination and ultrasound performed by the expert consultant on a follow-up visit occurring at the referral site. In addition to any diagnostic findings of significance which are missed, we will survey and document adverse events in the patient's subsequent course, both medical and social (e.g.: parent/baby separation, parental anxiety.) Each infant will be followed for 3 months from the time of the initial diagnosis encounter and will be compared to historical controls. Finally, our study will also include a financial outcomes/cost analysis.
Approach: This is a prospective, non-randomized, case-control study with measurements obtained at baseline (entry into the study) and three months later. Source data will consist of ultrasound images of the heart transmitted electronically from a remote site to a medical center where they will be read and interpreted. Non-transmitted U/S images and data abstracted from the infant's medical record will be recorded. Data will be obtained at baseline and three months following baseline. Recruitment and training of health care professionals: Two individuals - a pediatrician, family practitioner or obstetrical nurse from each designated participating center will be identified based on involvement in newborn care, interest, and availability for staffing in the nursery. Initial training in the use of handheld ultrasound systems will occur at Madigan Army Medical Center by Drs. Kinney and Puntel. The training will be offered twice and the individuals from each center will be assigned to participate in either the first or second sessions at Madigan. The training experience will consist of 2 days of classroom and individual hands-on instruction. A primer on ultrasound instrumentation and methods for performance of cardiac ultrasound will be prepared by Drs. Sahn, Kinney and Puntel who have long-term experience in teaching echocardiographic skills to residents, fellows and medical

students. The participants will review moving images on computer displays of echo findings for major forms of congenital heart disease and will review forms of congenital heart disease, diagnostic findings, signs and symptoms of congenital heart disease and theory and application of ultrasound. Instruction will include practicing ultrasound techniques and views on each other, reviewing recruitment policies, consent and data collection forms, and then hands-on practice with the portable echocardiogram machines on volunteer infants in the Madigan NICU or clinic. Infants whose families consent will be examined by the attending pediatric cardiologist and have hands-on scanning performed by the trainees under his supervision as the infant's condition allows. Infants will be kept warm and comfortable at all times. When the portable scanner becomes available for each center and the Telemedicine link is installed and activated, one of the four pediatric cardiologists staffing this program will visit with the trainees at each institution to bring the scanner and operate the telemedicine link, see patients and observe the trainees performing ultrasound examinations, especially in newborns. They will certify on that examination and/or by follow-up observation of Telemedicine observed studies by those healthcare provider-trainees when they are qualified to activate their site and enroll patients. Enrollment of patients will begin when all training has been completed and each center has completed its own IRB process. During this period, the telemedicine systems, the Polycom 512 that has been used in Portland for 5 years and has consistency of operation for image quality, transfer and face-to-face televideoconferencing, will be installed. Installations will occur as a collaboration between the telecommunications departments at OHSU and MAMC and staff at the individual centers, with the assistance of the telemedicine group of the Alaska Federal Health Care Network. The phone line infrastructure required has been confirmed to each site. Parents or surrogates will be informed about the study by the onsite team after it is confirmed that they completely understand the infant's medical condition. This will occur in a private setting in the patient's room or a conference room. The healthcare professional who has trained to perform the echocardiogram will be notified if they are not already the one initially evaluating the newborn. They will be the one to discuss the study and obtain consent. The physician or nurse will explain the baby's condition. The parents will be given time to discuss the infants condition and ask questions. When the parents appear to be ready to discuss the standard medical care the infant is receiving, the participating physician or nurse will review what diagnostic testing is available as a standard of care, and the option of participating in the study with the anticipation of perhaps clarifying the diagnosis. They will offer to the parent(s) the opportunity of an ultrasound examination to clarify the infant's condition, performed with remote supervision of a pediatric cardiology expert. The discussion related to consent would usually occur in the mother's hospital room on the post-partum floor. The family will be given time to discuss their willingness to have their infant participate in the study. Otherwise, health care will be routine for support and clarification of the infant's condition by routine diagnostic tests such as chest X-ray, EKG, or others as needed. The potential risks and potential benefits of choosing to participate or not will be discussed and the family will be assured that their decision to enter or not enter the study will not affect the infant's care (except for the need for consent and study entry before the ultrasound evaluation can be made available.) A colleague nurse or physician will serve as a witness for the informed consent process. The informed consent forms will be developed for use by each participating center following the master consent from approved by the Madigan IRB. Four copies of the form will be executed and the patient given a copy. One copy will be kept at the originating institution, one sent to the Madigan PI, and one kept in the patient's medical record. Other care of and testing of the infant will be performed as routinely by the hospital staff and

results will be extracted from the patient's medical record. Physical examination, EKG, and/or X-ray will be used, as routinely in a neonatal setting, for identification of potential signs, symptoms, physical examination findings, EKG or radiologic findings of congenital heart disease. Cyanosis will be detected by saturation meter and/or blood gases as necessary. These are part of routine Level II nursery care for newborn infants and will not be altered by the study. These protocols and methods may be specific to the site and documented in the approval of these sites as level 2 or level 3 nurseries.

Protocol Number: 203046 *Status:* Approved
Protocol Title: Telemedicine Based Ultrasound for Detecting Neonatal Heart Disease in Babies at Remote Military or Native American Health Care Facilities
Principal Investigator: Puntel RA (LTC Robert A. Puntel, MC)
Dept: Pediatrics

	When was the last progress submitted for this protocol:	**1/12/2004**
1.	**What is the new current reported protocol status:**	**Ongoing**
2.	**How many subjects have been enrolled at MAMC in the last 12 months?**	**0**
3.	**How many subjects have been enrolled at MAMC since study approval?**	**0**
4.	**Do you plan to enroll additional subjects at MAMC?**	**yes**
5.	**If a consent form was necessary, do you have an IRB stamped, signed, dated consent for each subject enrolled?** No subjects enrolled yet: awaiting HSRRB approval	**n/a**
6.	**Have any subjects received treatment on this study in the past 12 months?**	**no**
7.	**Are there any SAEs reported for this study that are <u>not</u> addressed in consent:**	**no**
8.	**Based on the type and number of SAEs/AEs reported for this protocol, do you think that any changes to the consent form are needed?** No subjects enrolled yet	**n/a**
9.	**Are you aware of any current or completed studies that provide information that would lead to changes to the current consent?**	**no**
10.	**Since the last IRB, have subjects been informed of any new information that might affect their willingness to continue participating in this research?** This is first review, no subjects enrolled	**n/a**
11.	**Have you made any changes to the way this protocol is performed as described in the "Methods" section of the protocol?**	**no**
12.	**Have there been any changes to the investigators or technical staff listed on this protocol?** Dr. J. Kinney is no longer an AI	**yes**

13. Summarized Progress: We have hired a Project Coordinator; we have received the tele-ECHO equipment for MAMC and the satellite sites. We are currently awaiting formal HSRRB approval. We are currently in the long process of linking Ft. Wainwright and Ft. Irwin via tele-medicine/internet links, which has many hurdles for AMO, HIPAA, security, firewalls, etc. No subjects have been enrolled for training or study as of 8 Jan 2004. -- R. Puntel, MD

Protocol for Training

The protocol for training will combine two teaching resources. One is: Sahn & Anderson, <u>Atlas of Echocardiographic Anatomy</u> (3), most specifically the anatomical drawings

(Appendix C), as well as World Echo on the Web, basic chapters on instrumentation and the chapter on congenital heart disease (Appendix D), and a CD based program we developed with a colleague in India (Appendix E).

One 2-day training session has been successfully completed for LTC Ronald Wells from Fort Wainwright. As mentioned, a training session has been scheduled for the end of April. We expect to train individuals from Fort Irwin in California. The Bethel and Anchorage Alaska Native health centers will be offered training in Anchorage, Alaska, in late May.

The data entry website has been completed and is available for review and practice sessions before final debugging at www.infantheartstudy.org. Sample pages are appended (Appendix F)

Key Research Accomplishments

Research accomplishments so far include the publication of a paper in the Journal of the American Society of Echocardiography (1) detailing our experience in neonatal diagnosis with handheld ultrasound systems.

The development of the remote control features of the telemedicine control of the SonoSite scanners by the remote expert, as described in the abstract enclosed, "Remote Optimization of Image and Diagnostic Quality During Real Time Telemedicine Echo Screening of Neonates at Risk for Cardiac Disease: A New Capability Developed in Support of Our DOD PRMRP Funded Study".

Human Subjects paperwork for training the participants, as well as for beginning the study is finalized. Final approval was given in mid February of 2004. Training sessions have been scheduled for April and May of 2004.

Reportable Outcomes

NONE

Conclusions

While somewhat delayed by involvement of military colleagues, in the interim period we worked very hard to firm up the Alaska Native Health Foundation participants and their telemedicine colleagues in Anchorage. They are anxious and ready to be connected at this time. We completed a survey of the infrastructure of all proposed sites, including the control sites.

We completed a verification of the performance of the SonoSite system in blinded observers. We completed a very difficult and detailed Human Subjects protocol, which is in the final stages of review, and which should be adoptable by individual hospitals in the network.

The website for the project data entry is available for testing and viewing, and will be available for the training sessions.

References

1. Li XK, Mack GK, Rusk RA, Dai X-N, El-Sedfy GOM, Davies CH, Sahn DJ. Will a handheld ultrasound scanner be applicable for screening for heart abnormalities in newborns and children? J Am Soc Echocardiogr 2003; 16(10):1007-1014
2. Sahn DJ, Catallo L, Puntel R, Kinney J, Martin P, Kinney E. Remote Optimization of Image and Diagnostic Quality During Real Time Telemedicine Echo Screening of Neonates at Risk for Cardiac Disease: A New Capability Developed in Support of Our

DOD PRMRP Funded Study. Presentation for PRMRP Investigators Meeting, Puerto Rico, April 2004.

3. Sahn DJ, Anderson F. Two-dimensional Anatomy of the Heart: An Atlas for Echocardiographers. New York, John Wiley & Sons, 1982

Appendices

A. Reference 1
B. Abstract, Reference 2
C. Anatomical Drawings from Reference 3
D. Essentials of Echocardiography #4
E. Slides Used for Course "Anatomic Basis of Echocardiography"
F. Sample Data Entry Pages for DOD Infant Heart Study

ORIGINAL ARTICLES

Will a Handheld Ultrasound Scanner be Applicable for Screening for Heart Abnormalities in Newborns and Children?

Xiaokui Li, MD, Gordon K. Mack, MD, Rosemary A. Rusk, MD, Xiao-Nan Dai, MD, Ghada O. M. El-Sedfy, MD, Crispin H. Davies, MD, and David J. Sahn, MD,
Portland, Oregon

Background: **There is significant interest in opportunities to provide echocardiography services for detection of congenital heart disease with portable, or even handheld, devices in remote areas or third world countries where conventional ultrasound systems may not be available. We tested a handheld system (HHS) (SonoHeart, SonoSite Inc, Bothell, Wash) equipped with a broadband, 7- to 4-MHz, miniaturized, curved, linear-array transducer and implemented with an improved directional Doppler flow map.**

Methods: **All echocardiography scanning was performed in the neonatal nursery, pediatric intensive care department, or pediatric echocardiography laboratory of our institution. We reviewed limited echocardiography view sequences sequentially obtained by the same expert examiner (D.J.S.) in 50 infants and children (age: 1 day to 6 years), with preoperative or postoperative forms of congenital heart disease. Each patient was studied twice, once with a conventional full-feature system (FFS) and then a limited scan with the HHS using similar frequency transducers. The cardiologist (D.J.S.) and blinded research laboratory reviewers (X.L., G.K.M., R.A.R.) read the FFS and HHS image sequences for diagnosis and for grading the quality of the anatomic and flow feature images. The studies were performed and reviewed with the examiner and reviewers blinded to patient diagnosis.**

Results: **The major diagnoses (eg, patent ductus arteriosus, atrio-ventricular (AV) canal, peripheral pulmonary valve stenosis, aortic coarctation, atrial septal defect, ventricular septal defect, preoperative or postoperative tetralogy of Fallot, and mitral regurgitation) were made by both readers, who were unaware of each other's diagnosis results. Furthermore, the average composite HHS cardiac anatomic feature score on a scale of 0 (not visualized) to 3 (visualized precisely) from the parasternal long-axis and 4- or 5-chamber view for cardiac anatomy were 2.67 ± 0.49 (SD) and 2.50 ± 0.55, respectively, versus 2.73 ± 0.45 and 2.55 ± 0.54 for the FFS. The mean flow feature score, comprising all views, was 2.67 ± 0.45 (HHS) versus 2.72 ± 0.48 (FFS). The *P* values for all above comparisons were >.05. Image quality of the FFS anatomic structures were, thus, not statistically different from the HHS. Although the color cosmetic was different for the HHS directional (nonvelocity) map, only 9% of 150 total findings (including structural abnormalities and flow features, none of which were critical) were missed, whereas the other 91% regurgitant, shunt, stenosis flow features or heart structure were imaged adequately by the HHS in this population.**

Conclusions: **Implementing high-frequency transducers and programs optimized for tissue and flow imaging on the HHS should provide images of sufficient quality for targeted echocardiography examinations to determine the presence, absence, or status of congenital heart disease in newborns and young children.** (J Am Soc Echocardiogr 2003;16: 1007–14.)

Real-time 2-dimensional (2D) echocardiographic methods have been the mainstay for clinical diagnosis and evaluation of congenital heart disease (CHD) for almost 25 years. Technical progress in ultrasonography in the last 10 years has been especially rapid as a result of continuing advances in transducer design, digital signal processing techniques, computer central processing unit speed, and digital memory for Doppler.[1,2] These technologies have enhanced both image and Doppler quality. Although most echocardiography systems are portable, it takes time to move the machine to the bedside. In busy medical centers there is often a lag time between a request for echocardiography and its completion and reporting.[2] A newly developed handheld ultrasound system (HHS) (SonoHeart,

From the Clinical Care Center for Congenital Heart Disease, Oregon Health and Science University.

Reprint requests: David J. Sahn, MD, The Clinical Care Center for Congenital Heart Disease, Oregon Health and Science University, L608, 3181 SW Sam Jackson Park Rd, Portland, OR 97239-3098 (E-mail: *sahnd@ohsu.edu*).

Copyright 2003 by the American Society of Echocardiography.

0894-7317/2003/$30.00 + 0
doi:10.1016/S0894-7317(03)00489-9

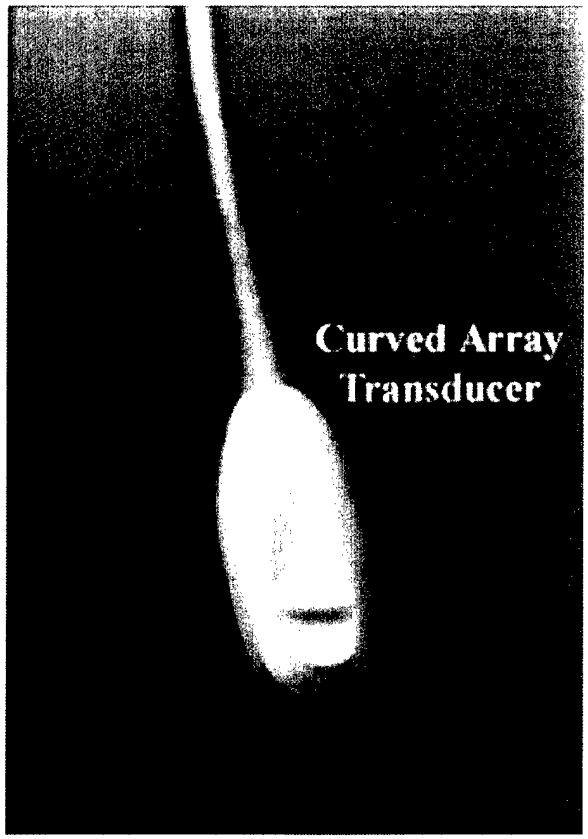

Figure 1 Miniaturized curved linear-array probe (7-4 MHz).

SonoSite Inc, Bothell, Wash) is one of the first all-digital HHSs. Although lacking in Doppler and M-mode features found on echocardiographic cart-based ultrasound full-feature systems (FFS), its use puts high-quality ultrasound imaging immediately in the hands of cardiologists wherever and whenever needed.[3-5] HHSs have only recently been objectively tested by cardiologists and have received somewhat varying reviews[6-9] for accuracy and diagnostic quality.

Because infants and young children are usually quite easy to image and their forms of heart disease are associated with significant alterations in chamber size, valve morphology, septation, or a combination of these, we tested the potential clinical applicability and accuracy of a HHS with a high-frequency transducer for detecting heart disease and monitoring transitional circulatory findings (patent foreman ovale [PFO], atrial septal defect, and patent ductus arteriosus [PDA]) in a tertiary level nursery and a pediatric outpatient echocardiography laboratory. The patients were scanned by a blinded expert examiner (D.J.S.). Results from the videotapes of these blinded HHS studies were compared with a complete examination performed on the same day by an echocardiographer on a FFS.

METHODS

Patient Population

In all, 50 infants and children (age: 1 day to 6 years) weighing 0.57 to 41 kg (mean 9.96 ± 10.47 kg), who had preoperative or postoperative forms of CHD were examined at the neonatal nursery, pediatric intensive care department, or outpatient echocardiography laboratory of our institution. Referral to the study was made consecutively for neonates, infants, and children referred for an echocardiogram for rule out (R/O) or known heart disease at a time when the examiner was available and the family was willing to sign the institutional review board-approved consent form for the study. Findings, diagnoses, or both present as documented on the echocardiography reports included: PDA (14); post-AV-canal repair (3); peripheral pulmonary valve stenosis (2); aortic coarctation (6); atrial septal defect (7); ventricular septal defect (VSD) (13); tetralogy of Fallot (4); pulmonary valve stenosis (8); PFO (14); and mitral regurgitation (12). Many patients had a combination of structural abnormalities with 1 or more of the above features.

Echocardiography and Image Acquisition

The FFSs listed below had 2D, velocity variance color Doppler, pulsed and CW spectral Doppler, M-mode, and electrocardiography (ECG). The HHS (SonoHeart, SonoSite Inc) was equipped with 2D and real-time directional color powered Doppler superimposed on the B-mode images over a 30-degree sector, but did not have an autocorrelation computed velocity variance color Doppler display, spectral pulsed or CW Doppler, M-mode traces, or an ECG. Lack of these features may potentially cause poor delineation of low-velocity regurgitant or higher velocity flows and we could not quantitatively evaluate aliased or turbulent flow as the FFS does. The HHS we tested in this study was programmed to scan with a new, broadband, 7- to 4-MHz, miniaturized, curved, linear-array transducer (Figure 1) optimized to image from 2- to 8-cm depths. The small-aperture curved array allowed us to image even superficial structures right to the skin line. Therefore, our preferred patient spectrum was less than 20 kg to limit our study to the applicability of the new high-frequency curved-array transducer that was made available to us. For each patient, 4-chamber, 4-chamber left ventricular outflow tract (LVOT), parasternal long-axis, short-axis, subcostal, and suprasternal views with and without color Doppler interrogation were obtained. All views were recorded on a miniature digital video recorder. Parasternal and suprasternal views were combined as long-axis; subcostal and apex views were combined as 4-chamber and 4-chamber LVOT views. These same views were obtained at a different time by a registered diagnostic medical

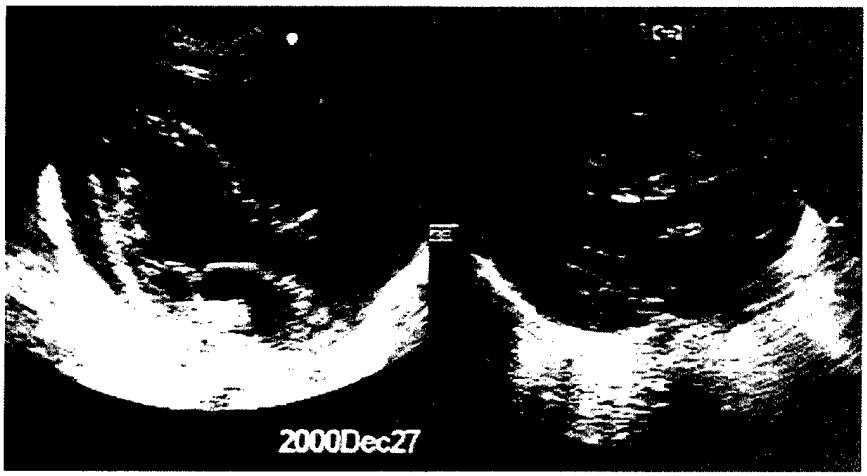

Figure 2 Comparison of cardiac anatomy from handheld (*left*) and full-feature (*right*) system. Two-month-old patient with congenital mitral valve disease resulted in left ventricle hypertrophy and pericardial effusion.

sonographer (RDMS)- or registered cardiovascular technologist (RCVT)-credentialed, fully trained, pediatric echosonographer selected by random assignment to do the study on a FFS (Agilent 5500, Hewlett Packard, Andover, Mass; Toshiba 8000, Toshiba, Tokyo, Japan; or Sequoia, Acuson, Mountain View, Calif) running similar frequency (5- to 7.5-MHz) transducers. All images were recorded for the FFS on an onboard super VHS videocassette recorder as part of a complete echocardiography study, including M-mode spectral traces and color Doppler in each view. On notification that an echocardiogram had been requested or scheduled from the pediatric echocardiography laboratory, a single expert examiner (D.J.S.) performed a HHS study before or after the FFS study and without knowledge of any clinical data. The examiner did not examine the patient or look for syndrome appearance, nor had he seen charts, previous echocardiograms, or any of the images on the FFS. Informed consent for a limited HHS echocardiography study was obtained from each patient's parents under institutional review board approval.

Evaluation and Reviews

The FFS system readings by a board-certified pediatric cardiologist (a staff member other than D.J.S. in the Division of Pediatric Cardiology at our institution) were considered the gold standard for diagnostic features. These reports and the videotape of these FFS studies were then compared with the videotaped studies from the HHS device. A separate reviewer (X.L.) from our institutional Cardiac Fluid Dynamics and Imaging Laboratory read the HHS images for diagnostic findings. Lastly, at another time, 2 research staff image-quality reviewers (G.K.M., R.A.R.) separately graded the FFS and HHS studies structure by structure in each view to evaluate the quality of the anatomic and flow feature images (each graded with a scoring system: 0 = not visualized; 1 = visualized but not adequately; 2 = visualized adequately; 3 = visualized very well). The research staff performed grading reviews separately without knowledge of each other's results. Grades were then averaged and compared.

Statistical Analysis

All comparisons were stated as mean ± SD. The graded scores for the 2D B-mode structure visualization and color Doppler imaging quality for the HHS and the FFS were compared for statistical significance by related sample sign test (nonparametric distribution free statistics), because the same patients were studied by both systems and the data were not continuous. A P value of less than .05 was considered to be statistically significant.

RESULTS

For the 50 patients referred from the nursery, intensive care department, and outpatient echocardiography laboratory settings, essentially the same diagnosis (Figures 2 to 5) was made by the pediatric cardiologist reading the FFS and the research laboratory reader reading the HHS echocardiogram, each unaware of the other's results. Compared with 2D echocardiography and color Doppler on the FFS, 2 small and restrictive muscular VSDs (patients 22 and 30) and 2 small PFOs (patients 16 and 39) were missed on the reading of the HHS examination; also 2 labile PDAs (patients 3 and 14) were graded smaller on the HHS examination than on the FFS. However, they were noted to change caliber and degree of shunting in both studies. The average anatomic feature scores (B-mode) of the 2 image-

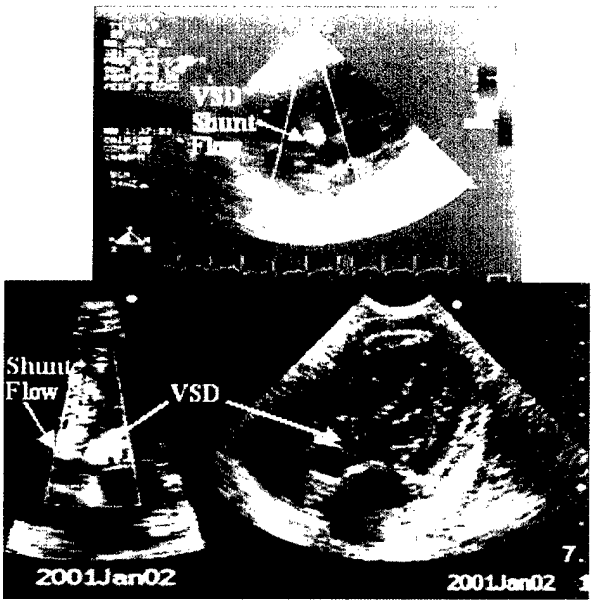

Figure 3 Four-month-old patient with ventricular septal defect (*VSD*) imaged by handheld (*bottom*) and full-feature (*top*) systems in apex view. *Arrows* show position of VSD and shunt flow.

quality reviewers showed a composite HHS mean score from long-axis and 4- or 4-chamber LVOT views of 2.67 ± 0.49 (SD) and 2.50 ± 0.55, respectively, versus 2.73 ± 0.45 and 2.55 ± 0.54 for the FFS (P = .13 for long-axis and P = .11 for 4- or 4-chamber LVOT views). The mean color flow features, averaging all views, were 2.67 ± 0.45 (HHS) versus 2.72 ± 0.48 (FFS) (P = .07) (Figure 6). HHS image quality was, thus, not statistically different from the FFS. Although the color Doppler cosmetic in the color flow map available for the HHS was different, only 9% of the total of 150 diagnostic findings were difficult to perceive clearly; that includes 3% of heart structure defects (2 small muscular VSDs [patients 22 and 30] and 2 small PFOs [patients 16 and 39]) and 6% of mild valve insufficiency findings (including physiologic tricuspid insufficiency/tricuspid regurgitation [TI/TR] jets [patients 2, 5, 28, 36, 43, and 49], mild pulmonary insufficiency [PI]/pulmonary valve stenosis [patients 2, 18, and 36], and aortic insufficiency [AI] [patient 47]) that were missed. The other 91% of the total findings, including regurgitant flow or visualization of shunt flow and/or stenosis findings, were imaged



Figure 4 Two-dimensional anatomic comparison of aortic coarctation (*CoA*) (*arrow*) imaged by handheld (*HHS*) and full-feature (*FFS*) systems. *AO*, Aorta.



Figure 5 Color flow of patent ductus arteriosus (*PDA*) imaged with handheld system directional (power Doppler nonvelocity) map (*left*) compared with that imaged with full-feature system velocity color Doppler (*right*).

adequately with the HHS in this population. Detailed patient diagnosis and categorized diagnosis comparisons for both FFS and HHS are shown in Tables 1 and 2.

DISCUSSION

The contribution of echocardiography to the diagnosis and understanding of cardiovascular disease during the last 30 years has been truly remarkable.[6] We now take for granted that we can "see" the heart dynamically and image the blood flow (Doppler velocity) with echocardiography. This technique has also been of great benefit for evaluation of valvular heart disease and cardiomyopathies. A recent clinical study[7] showed that physical examination failed to detect 59% of all cardiovascular conditions and 43% of the major findings when compared with ultrasound imaging. One of the reasons for this unfortunate decline is the decreased attention to training and skill in performing physical examinations, and the ease with which health professionals can gain quantitative and qualitative information about the diagnosis of heart disease using echocardiography.

A reality of the impact in echocardiography is that highly skilled technical personnel make this excellent tool widely available for the diagnosis and assessment of patients with cardiac conditions when indicated. However, there is a shortage of adequately trained sonographers and the conventional cart-carried ultrasound machine on wheels, which has been used for the past 3 decades, does not always meet in timely fashion the demand for echocardiography at the bedside. It is also hard to set up traditional FFS studies outside hospital centers, like satellite clinics or rural areas. The HHS was introduced at a relatively low cost, it weighs less than 6 pounds, and runs on battery power.[5] We could obtain the basic cardiac views required to evaluate CHD using the HHS with a high-frequency transducer in our study. Image quality with the high-frequency array used in this easy-to-image population of children and infants corresponded closely with the image quality seen on the FFS examinations.[6,10] A range of congenital cardiovascular conditions can be diagnosed adequately when compared with the FFS results, detecting anatomic findings with very high sensitivity. As we have mentioned, although our preferred patient spectrum was less than 20 kg, we still had 8 patients who weighed more than 20 kg when we updated the patient information. Despite this, among these 8 patients, there were only 2 missed findings of very mild valvular regurgitation (patients 2 and 5) with the HHS. Thus, we would conclude that for older children, this high-frequency array system could be applied by an expert scanner if the suitable lower frequency transducer is not available.

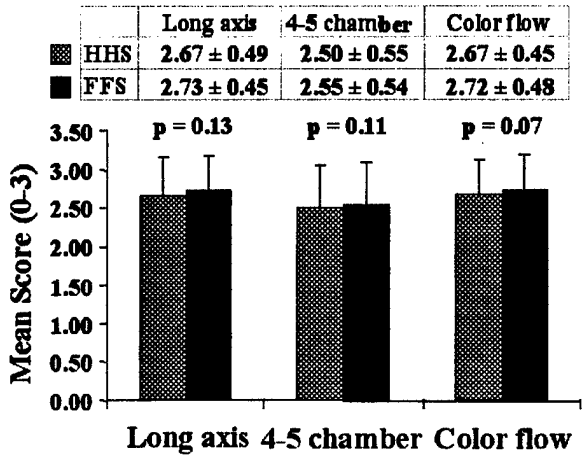

Figure 6 Bar graph for full-feature (*FFS*) and handheld (*HHS*) system scores: 0 = not visualized; 1 = visualized but not adequately; 2 = visualized adequately; 3 = visualized very well. *5-chamber* = 4-chamber left ventricular outflow tract view.

Early Use of HHS Devices

In the early 1970s, one of the first 2D echocardiographic instruments was miniaturized for use at the bedside.[11] Unfortunately, although the idea was precocious and the engineering was impressive in its time, the quality of the images obtained with a linear array and the cost of the instrument limited its applicability. The 2 recently developed HHS machines have been used with favorable results in helicopters,[3] on outpatients, during hospital rounds,[8,12] and in intensive care or emergency departments.[4,8,13-15] Studies have reported that there is a good correlation between FFS and HHS findings for evaluation of a variety of cardiovascular diseases.[16] Our study is a demonstration that common forms of CHD-especially in those patients whose hearts have major structural malformations-can be identified with a HHS and a high-frequency array, as can associated atrial or ductal shunt characteristic of the transitional circulation in neonates. In this study, although we could routinely detect entry of flow from all 4 pulmonary veins on apex, subcostal, and coronal suprasternal views, we did not encounter any anomalies of pulmonary drainage. It remains to be demonstrated how effective handheld scanners will be in completely detailing the spectrum of pulmonary venous anomalies. Likewise, we did not encounter any infants or children with anomalies of the coronary arteries.

Limitations of the HHS

Color Doppler map. Although our quality analysis of the HHS images with the directional (power

Table 1 Comparison of diagnosis using different ultrasound systems

No.	Age	Weight (kg)	FFS findings	HHS findings
1	15 d	1.75	Large PDA, ASD, mild TI, LVE	Large PDA, ASD, LVE, tiny TI
2	5 y	41	Physiologic TI and PI, mildly increased velocity in ascending AO	Normal echo, TI and PI flow missed, normal Ao flow
3	21 d	3.29	Small PDA, physiologic PPS	Tiny PDA, physiologic PPS
4	5 y	38	CM, mild AI, Physiologic PI	CM, mild AI, physiologic PI
5	4 y	30.5	Normal echo, physiologic TI	Normal echo, TI missed
6	2 d	2.15	CoA, moderate LVH, PE, MS, physiologic PI, TI	CoA, MS, LVH, PE, physiologic PI, TI
7	7 mo	6.7	Subaortic VSD extending to inlet, moderate PS	Large inlet VSD, RVH, PS
8	4 mo	5.9	Mild PS, PFO	Mild PS, PFO
9	2 y, 4 mo	8	P/O AV canal, mild MR, and TI	Mild MR and TI
10	1 d	3.9	TOF, PDA, PFO	TOF, small PAs, PDA, PFO
11	1 mo	4.3	P/O TOF, mild PS, moderate TI, ASD, trivial AI, MR	P/O TOF, mild PS, TI, ASD, AI, MR
12	12 d	4	PFO	PFO
13	4 y, 6 mo	21.8	P/O AV canal, no residual shunt, mild MR, mild TI	MR, mild TI
14	5 d	1.18	Small PDA	Labile tiny PDA, normal LV function
15	4 d	3.5	CoA, hypoplastic trans AO arch, large PDA bi direction shunt, mild MR, PFO	CoA, hypoplastic trans AO arch, bidirectional PDA, MR, PFO
16	2 d	3.72	RVH, LVH, dilated CA, small PE, small PDA, small PFO	RVH, LVH, dilated CA, small PE, PDA, PFO missed
17	3 d	2.5	Mild MR, physiologic PI	Mild MR, physiologic PI
18	2 d	0.79	PDA, ASD, mild TI, MR, PI, small atrial septal aneurysm, LVE	PDA, ASD, MR, PI, TI, atrial septal aneurysm and LVE, PI missed
19	3 d	2.06	CoA, very large PDA, PFO, transverse Ao arch hypoplasia	CoA, large PDA (L-R shunt), PFO, transverse Ao arch hypoplasia
20	11 d	0.92	VSD, mild LPA turbulence	Bidirectional VSD
21	4 d	0.57	Large PDA, LVE, PFO, mild TI	Large PDA, marginal LVE, PFO and TI
22	7 d	1.45	Very small muscular VSD, small PDA, ASD bidirectional shunt	Small PDA and ASD, VSD missed
23	4 d	0.97	Moderate PDA continuous left to right shunt, PFO, LVE	PDA L-R shunt, PFO and LVE
24	7 d	2.46	PDA, small muscular VSD, PFO, LVE, LAE	PDA, small muscular VSD, PFO, LVE, LAE
25	2 mo	5.1	P/O VSD and ASD repair, mild TI and MR	Mild MR, tiny TI
26	1.5 mo	3.5	P/O CoA, LVH, PFO	Mildly reduced Aortic dimension, LVE, LVH, PFO
27	2 d	2.5	HCM, LVOT obstruction, mild MR, large PFO, small PDA	HCM, Narrow LVOT, MR, PFO, small PDA
28	5 d	2.8	Partial AV canal, small TR, PFO, small jet of cleft into RA	Partial AV canal, LV to RA shunt, primum ASD and PFO, TR missed
29	4 mo	8.4	PPS, mild MR, PFO	PPS, PFO, mild MR
30	2 mo	4.05	VSD, PFO	PFO, VSD missed
31	6 y	28.2	Ao root enlargement, mild MVP and MR, mild TI and PI	Ao root enlargement, MVP and tiny MR, mild TI and PI
32	6 y	31.9	P/O PDA coil, LVE, mild CoA, mild TI	P/O PDA coil, LVE, mild CoA, small TI
33	1 y	6.6	Normal echo scan	Normal echo
34	18 mo	10.6	Mild TI	Mild TI
35	2 y	25	P/O Fontan, DORV, severe MS, small LV, normal PA flow, mild TI	P/O Fontan, DORV, small LV, severe MS and mild TI
36	4 y	18.2	Transposition of the great arteries, VSD, PS, mild TI	Transposition of great arteries, muscular VSD, PS and TI flow missed
37	6 mo	4.92	TOF	TOF
38	4 y	15.4	Mild LVE, physiologic TI	Mildly enlarged LV, tiny TI
39	4 mo	4.5	P/O CoA residual narrowing (5.5 mm) between IA and LCA, PFO, moderate high muscular VSD L-R, mild MS (mean grad 9.3 mmHg), mild MR, bileaflet AoV	Moderate narrowing Ao arch between IA and LCA, VSD L-R shunt, MS, mild MR and bileaflet Ao valve, PFO not found
40	3 y, 5 mo	17.7	Tiny anterior muscular VSD	Small VSD
41	2 y, 3 mo	15.2	Normal echo scan	Normal heart structure and function
42	3 mo	5	Two muscular VSDs, normal estimated RV pressure	Two muscular VSDs

(continued)

Table 1 Continued

No.	Age	Weight (kg)	FFS findings	HHS findings
43	2 y, 8 mo	12	Large perimembranous VSD, moderate shunt, bicuspid Ao valve with minimal AS, LVE, mild TI	Large perimembranous VSD L-R shunt, bileaflet Ao valve, LVE, and AS, TI missed
44	3 y, 7 mo	15	HLHS, P/O DKS, Fontan, Damus anastomosis is widely patent. Systemic venous tunnel is widely patent; no thrombus seen, ventricular function is low normal.	P/O DKS, Fontan, single right ventricle with systemic venous tunnel widely patent, nearly normal ventricular function
45	3 y, 9 mo	19	DCM, LVE, mild MR, mild TI	DCM, LVE, MR, mild TI
46	4 mo	5.6	LPA stenosis	Mild LPA stenosis
47	1 mo	4.6	DORV, VSD L-R, ASD, AI, MR,	DORV, VSD L-R shunt, ASD, MR, AI missed
48	6 y	27.3	P/O VSD, sub PS, PI	P/O sub PS, PI
49	11 mo	9.1	Slight LVE, physiologic TI	Marginal LVE, TI missed
50	1 mo	4.55	TOF, severe PS, hypoplastic PA, PDA	TOF, PS, hypoplastic PA, PDA

FFS, Full feature system; *HHS*, hand held system.
Valve disease: AI, Aortic insufficiency; *AR*, aortic regurgitation; *AS*, aortic valve stenosis; *MR*, mitral regurgitation; *MVP*, mitral valve prolapse; *MS*, mitral stenosis; *PI*, pulmonary insufficiency; *PS*, pulmonary valve stenosis; *TI*, tricuspid insufficiency.
Heart structure defect: ASD, Atrial septal defect; *AV canal*, atrio-ventricular canal defect; *TOF*, tetralogy of Fallot; *VSD*, ventricular septal defect; *DORV*, double outlet right ventricle; *HLHS*, hypoplastic left heart syndrome; *PA*, pulmonary artery.
Great vessel abnormality: CoA, Aortic coarctation; *PDA*, patent ductus arteriosus; *PPS*, peripheral pulmonary stenosis.
Other heart abnormality: CM, Cardiomyopathy; *DCM*, dilated cardiomyopathy; *HCM*, hypertrophic cardiomyopathy; *LAE*, left atrial enlargement; *LVE*, left ventricular enlargement; *RAE*, right atrial enlargement; *RVE*, right ventricular enlargement; *LVH*, left ventricular hypertrophy; *RVH*, right ventricular hypertrophy; *PE*, pericardial effusion. *CA*, coronary artery; *IA*, innominate artery; *LPA*, left pulmonary artery; *LCA*, left common carotid artery; *P/O*, post operation status; *DKS*, Damus Kaye Stansel surgery; *AoV*, aortic valve.

Table 2 Comparison of FFS and HHS findings in different categories

Category	Total findings	FFS findings	HHS findings	HHS miss findings more than 150 cases
Heart structure	50	50 (100%)	46 (92%)	4 (3%)
Valve structure	49	48 (98%)	40 (82%)	9 (6%)
Great vessel abnormality	25	25 (100%)	25 (100%)	0 (0%)
Other heart abnormality	26	26 (100%)	26 (100%)	0 (0%)
Total	150	149 (99%)	137 (91%)	13 (9%)

FFS, Full feature system; *HHS*, hand held system.

Doppler nonvelocity) map available to us showed no significant difference from the FFS color Doppler imaging, a few valve disease-related findings (physiologic TI/TR jets, pulmonary insufficiency, and aortic insufficiency) and 3% (2 small muscular VSDs, 2 PFOs) of the heart structure-related findings were missed (Table 2). The color power Doppler implemented on this product is currently limited, in that it measures the amplitude and direction of the Doppler signal and does not actually quantitate the magnitude of the Doppler velocity shift as compared with standard velocity variance color Doppler displays. Therefore, velocity is not measured, and the mosaic velocity and variance patterns widely used in delineation of turbulent flow are not displayed.[8] For this reason, some small regurgitant flow, mild stenosis, and tiny septal defects with low velocity flows might be missed. In fact, 9% of a total of 150 findings (including structural abnormalities and flow features, none of which were critical) were missed. This will better explain the missed findings of our study as compared with the FFS. We believe further development of the next generation HHS will implement a full velocity variance color Doppler to overcome the problems encountered.

Spectral Doppler. The HHS system we used was not equipped with ECG, spectral Doppler, or M-mode, which limits the ability to determine flow timing and quantitate spectral velocity patterns. Simple M-mode measurements, widely performed for mass and function, cannot be made. The lack of spectral Doppler could have impaired diagnosis. It did not, but undoubtedly the absence, especially of CW spectral Doppler, hampered evaluation of the severity of stenosis of valves and aortic coarctation. The study by Goodkin et al[8] also suggested incomplete diagnosis occurred with a HHS in adult patients who were critically ill studied with a similar system that did not allow spectral Doppler, ECG, and M-mode capabilities or true velocity variance color flow Doppler imaging. The miniaturized transducer (Figure 1) and the young patient population made our scanning easier, yielding clear images. The thin chest wall, lack of rib shadowing, and wide

range of ultrasound windows in infants contributed to the clearer images. Further, the curved array has better near-field resolution very close to the transducer than some phased-array transducers when used at similar frequencies. A newer model (SonoHeart Plus, SonoSite Inc) has been already introduced with M-mode, ECG, and pulsed and CW spectral Doppler, and another product line (Optigo, Philips Ultrasound, Andover, Mass)[7] has a full high-resolution velocity variance display for color Doppler, but currently only functions at 2.5 MHz. The critical issue for diagnosis in the population we studied is training and expertise of the scanner. Our study, thus, would be a best case result for using this system for evaluation of patients with CHD, because the scanner was a true expert with many years of experience in pediatric cardiology. It does not project on what could be obtained with examinations performed by minimally trained scanners with or without remote supervision by telemedicine lines,[5] but projects on studies performed by a qualified sonographer and interpreted by a pediatric cardiologist. Our study does not address all the issues of training, which will ultimately determine the use and effectiveness of these devices in the multiple arenas in patient care.

Conclusions

Even in the face of the technical progress expected for the HHS where all of the features in a FFS could be offered, our study has demonstrated that HHS in its current configuration, running with a high-frequency ultrasound array, reliably diagnosed a wide range of CHD or transitional circulation findings (PFO, atrial septal defect, PDA) in newborns and young children. We expect that ultimately the application of HHS may be limited only by the skill of the person scanning, and not by size or price. When used by a trained and astute scanner, it is likely that the HHS will result in accurate evaluation of the heart in locations where the FFS may be less easily available. This could improve medical care delivery and make echocardiography more widely available for infants and children with CHD.

REFERENCES

1. Chou YH. Technological progress in ultrasonography. J Formos Med Assoc 1999;98:749-56.
2. Schiller NB. Hand-held echocardiography: revolution or hassle? J Am Coll Cardiol 2000;37:2023-4.
3. Price DD, Wilson SR, Murphy TG. Trauma ultrasound feasibility during helicopter transport. Air Med J 2000;19:144-6.
4. Wherry DC. Potential of a hand-held ultrasound in assessment of the injured patient. Cardiovasc Surg 1998;6:569-72.
5. Seward JB, Douglas PS, Erbel R, Kerber RE, Kronzon I, Rakowski H, et al. Hand-carried cardiac ultrasound (HCU) device: recommendations regarding new technology; a report from the echocardiography task force on new technology of the nomenclature and standards committee of the American Society of Echocardiography. J Am Soc Echocardiogr 2002;15:369-73.
6. Popp RL. The physical examination of the future: echocardiography as part of the assessment. ACC Curr J Rev 1998;7:79-81.
7. Spencer KT, Anderson AS, Bhargava A, Bales AC, Sorrentino M, Furlong K, et al. Physician-performed point of care echocardiography using a laptop platform compared with physical examination in the cardiovascular patient. J Am Coll Cardiol 2001;37:2013-8.
8. Goodkin GM, Spevack DM, Tunick PA, Kronzon I. How useful is hand-carried bedside echocardiography in critically ill patients? J Am Coll Cardiol 2000;37:2019-22.
9. Kimura BJ, Blanchard DG, Willis CL, DeMaria AN. Limited cardiac ultrasound examination for cost-effective echocardiographic referral. J Am Soc Echocardiogr 2002;15:640-6.
10. Pritchett AM, Bruce CJ, Bailey KR, Tajik AJ, Seward JB. Personal ultrasound imager: extension of the cardiovascular physical examination [abstract]. J Am Soc Echocardiogr 2000;13:485.
11. Roelandt J, Wladimiroff JW, Baars AM. Ultrasonic real time imaging with a hand-held scanner. Ultrasound Med Biol 1978;4:93-7.
12. Rosenberg ER, Grossman H, Bowie JD, Ram PC. Extracranial cribside sonography in infants. South Med J 1984;77:968-71.
13. Markowitz RI. Radiologic assessment in the pediatric intensive care unit. Yale J Biol Med 1984;57:49-82.
14. Cohen A. The best in 2000 on echocardiography. Arch Mal Coeur Vaiss 2001;94:27-39.
15. Turturro MA. Emergency echocardiography. Emerg Med Clin North Am 1992;10:47-57.
16. Vourvouri EC, Poldermans D, Schinkel AF, Sozzi FB, Bax JJ, van Urk H, et al. Abdominal aortic aneurysm screening using a hand-held ultrasound device: "a pilot study". Eur J Vasc Endovasc Surg 2001;22:352-4.

Appendix B. Abstract, Reference 2

REMOTE OPTIMIZATION OF IMAGE AND DIAGNOSTIC QUALITY DURING REAL TIME TELEMEDICINE ECHO SCREENING OF NEONATES AT RISK FOR CARDIAC DISEASE: A NEW CAPABILITY DEVELOPED IN SUPPORT OF OUR DOD PRMRP FUNDED STUDY

David J. Sahn, MD, Leo Catallo, MS, LTC Robert Puntel, MD, COL James Kinney, MD, Patrick Martin, Elizabeth Kinney

Oregon Health & Science University, Portland, OR

sahnd@ohsu.edu

Background/Purpose: Our DOD program "Telemedicine Based Ultrasound for Detecting Neonatal Heart Disease in Babies Born at Remote Military or Native Alaskan Health Care Facilities" is a partnership between Oregon Health & Science University (OHSU), in Portland, OR, Madigan Army Medical Center (MAMC) at Fort Lewis, WA, and SonoSite, Inc. in Bothell, WA. We are training nurses and pediatricians at remote facilities in the NW and Alaska who work in settings where expertise and equipment to perform echocardiography in neonates is lacking. After training at MAMC, these individuals will return to their remote facility with a SonoHeart Elite™ system equipped with a C11/7-4MHz transducer while program staff completes installation of Polycom systems for interactive telemedicine remote supervision of their examinations by expert Pediatric Cardiologists at OHSU and MAMC.

Methods: In support of our program, a proprietary, investigational software program was developed by SonoSite to allow the remote control of a SonoSite Hand Carried Ultrasound (HCU) system. The purpose of this software is to allow an expert clinician who is at a PC terminal remote from the HCU device itself to control key trackball functions (e.g., placement of the m-line, a sample volume, color ROI box, and/or measurement calipers) of the HCU device. This is intended to facilitate the performance of an echocardiogram that is performed with the HCU by a less experienced operator.

Results: This software runs on a standard Pentium PC platform and utilizes a Windows based GUI, which is controlled by a mouse. The HCU is interfaced with the PC via a serial port that can be accessed either directly on the HCU system or on an optional, commercially available mobile docking station. This clinical site PC is interfaced with a high-speed Internet connection to allow communication with a similar PC at a remote location where the expert clinician is located.

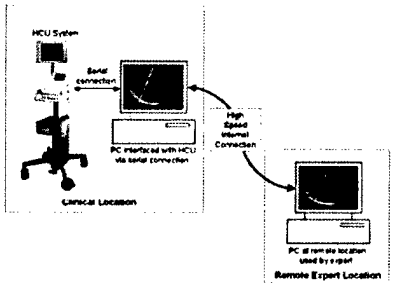

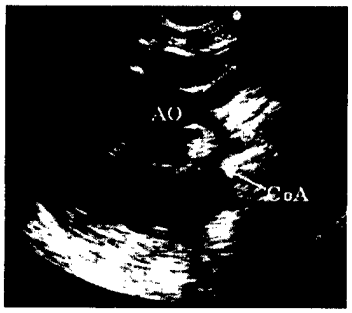

Conclusions: The Internet based system allows remote image optimization by the expert, while a standard Polycom FX video and audio communication system allows the transmission of real time images from the HCU to the remote expert and voice communication with the clinical operator.

The US Army Medical Research and Materiel Command under DAMD17-03-1-0109 supported this work.

Appendix C. Anatomical Drawings from Reference 3.

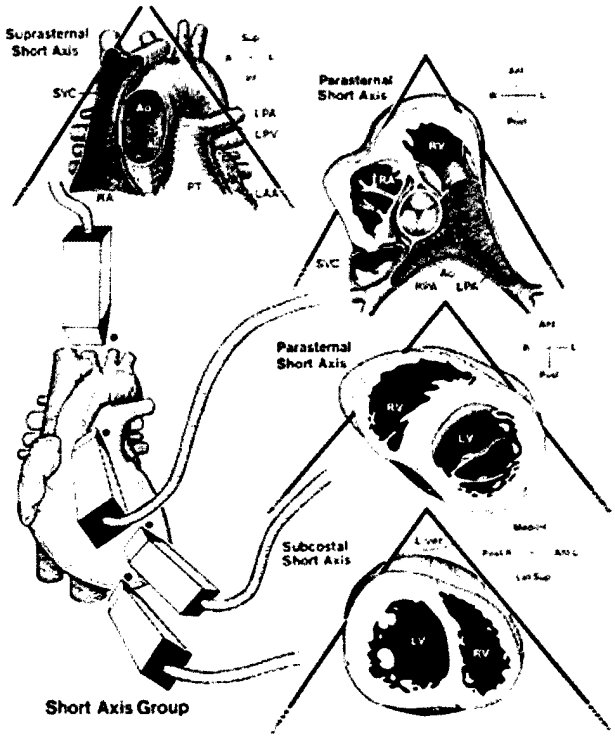

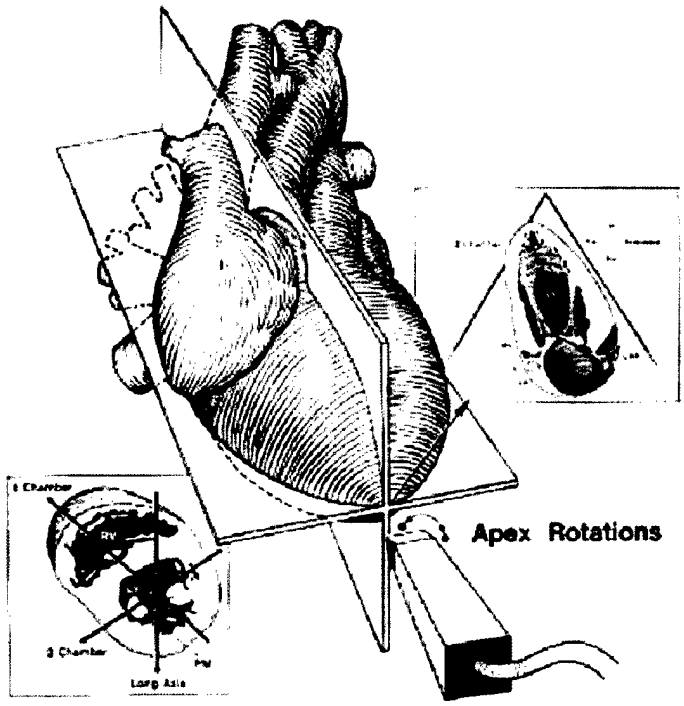

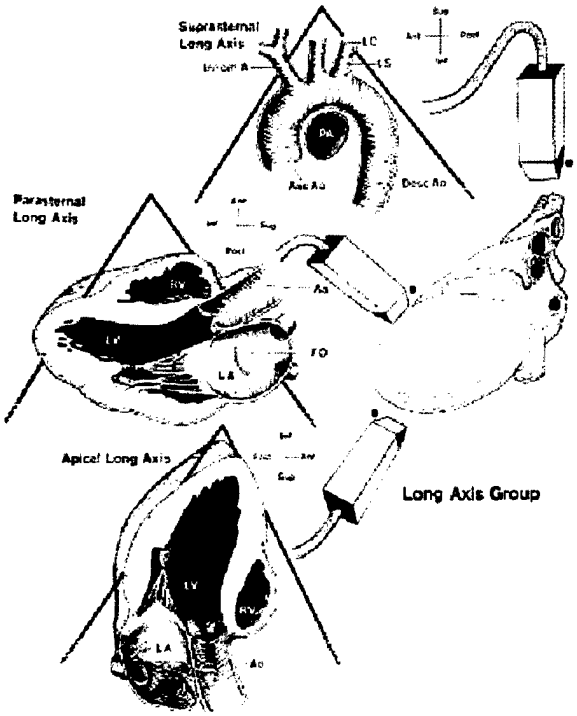
Suprasternal
Long Axis
Parasternal
Long Axis
Apical Long Axis
Long Axis Group

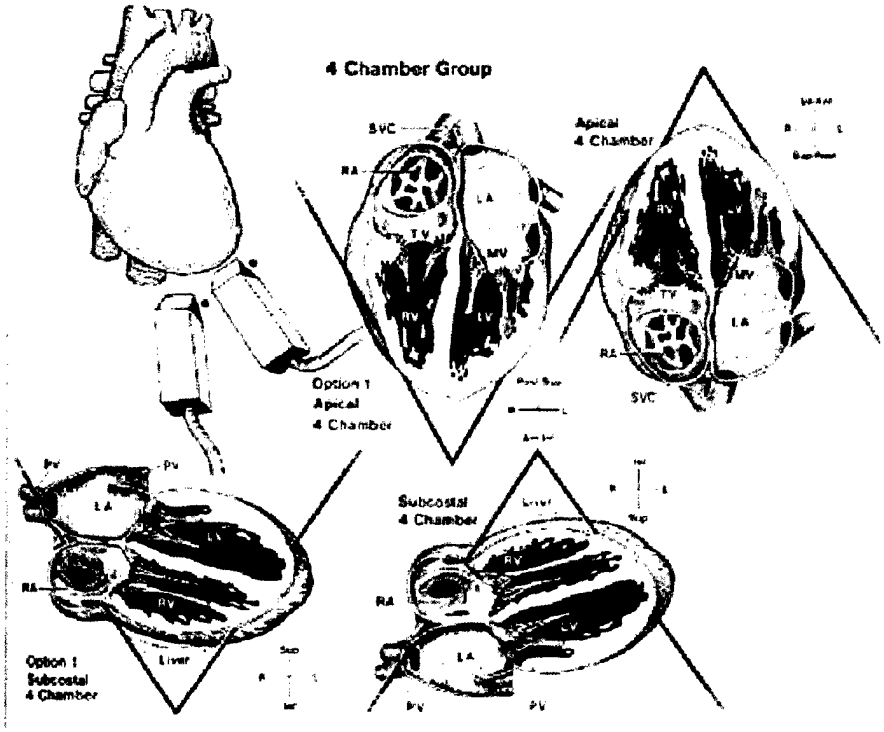
4 Chamber Group
Apical
4 Chamber
Option 1
Apical
4 Chamber
Subcostal
4 Chamber
Option 1
Subcostal
4 Chamber

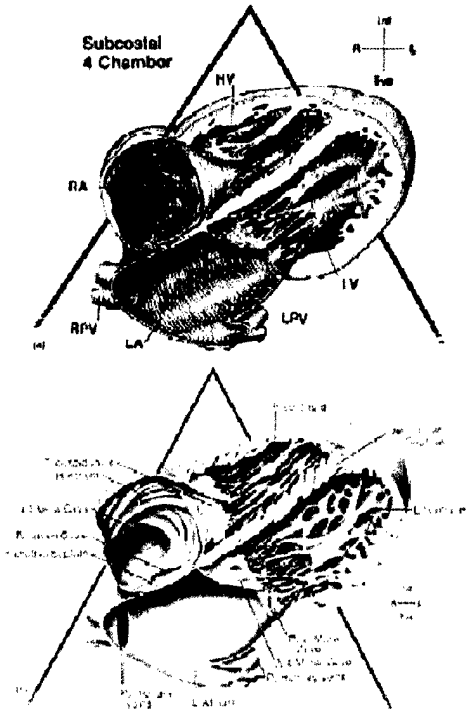
Subcostal
4 Chamber
RV
RA
LV
RPV
LA
LPV

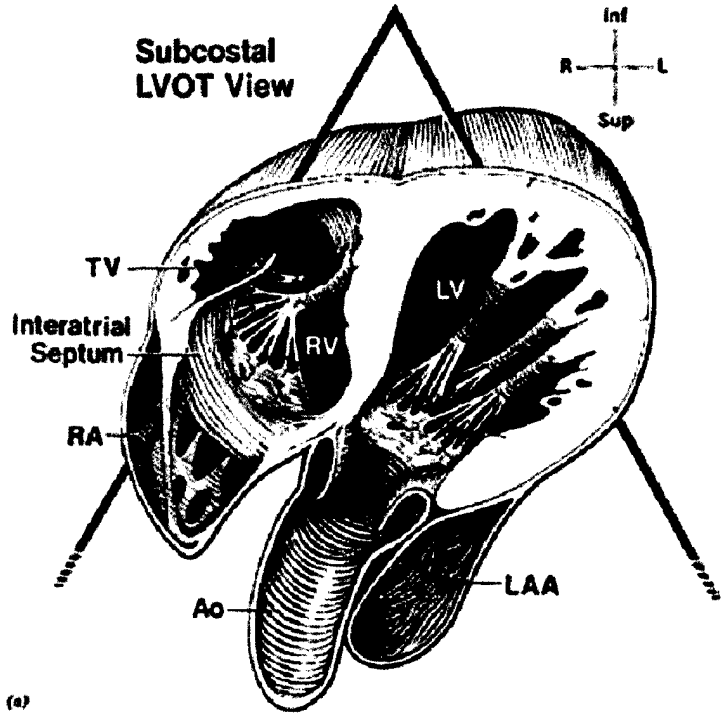
Subcostal
LVOT View
Inf
R
L
Sup
TV
Interatrial
Septum
RA
RV
LV
Ao
LAA

(a)

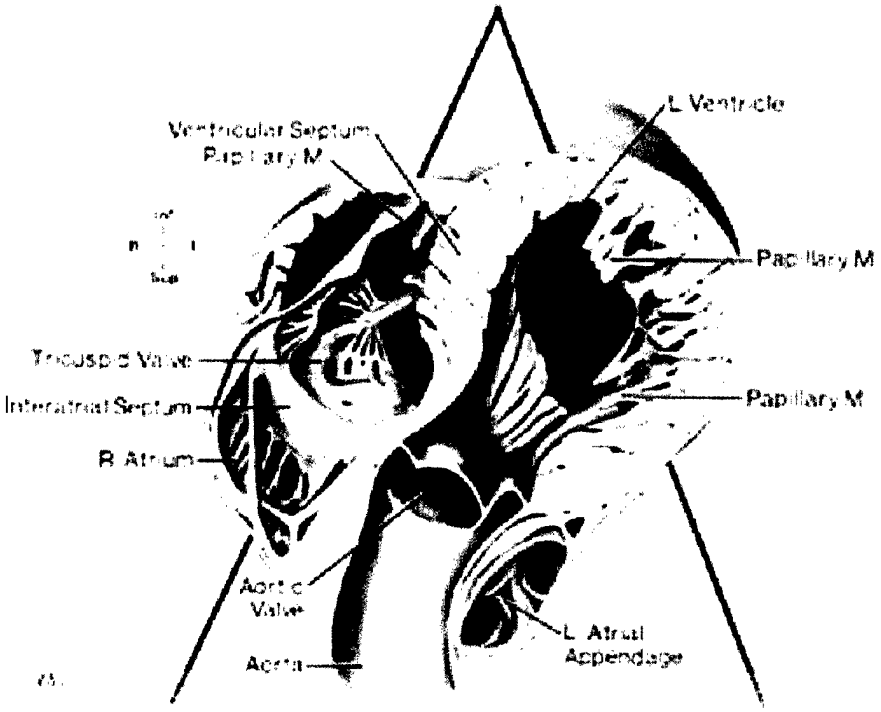
L Ventricle
Ventricular Septum
Papillary M
Papillary M
Tricuspid Valve
Interatrial Septum
Papillary M
R Atrium
Aortic Valve
L Atrial Appendage
Aorta

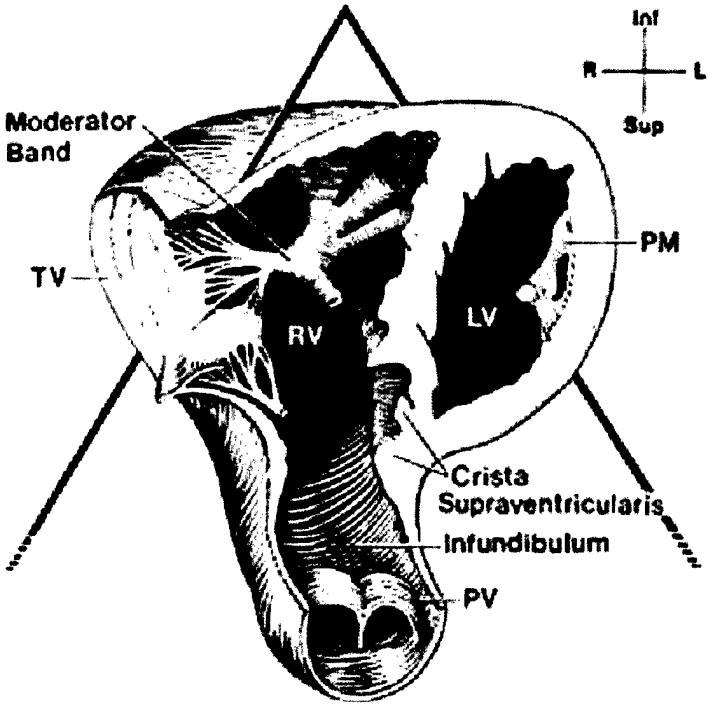
Inf
R
L
Sup
Moderator Band
PM
TV
RV
LV
Crista Supraventricularis
Infundibulum
PV

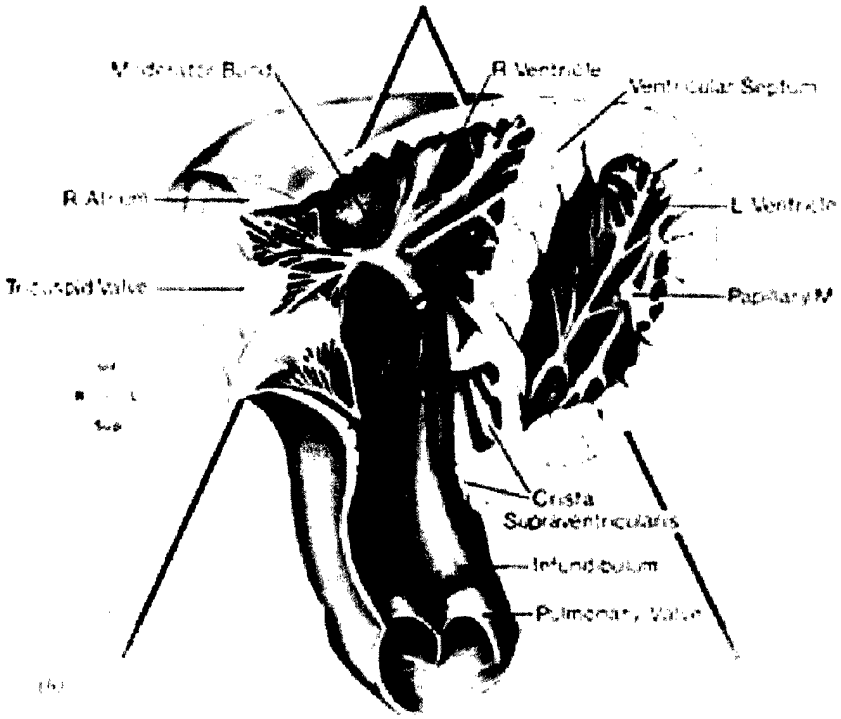
R Ventricle
Ventricular Septum
R Atrium
L Ventricle
Tricuspid Valve
Papillary M
Crista
Supraventricularis
Infundibulum
Pulmonary Valve

APPENDIX D. Essentials of Echocardiography #4

The Use of Echocardiography in Congenital Heart Disease

Joseph A. Kisslo, MD; David B. Adams, RDCS; Graham J. Leech, MA

Two-dimensional echocardiography is ideally suited for the evaluation of congenital heart disease because of its ability to visualize cross-sections of complex cardiac anatomic structures. Visualizing heart walls, chambers, and valves, it is, in many ways, superior to angiography for revealing complex spatial morphologic information.

This unit discusses the use of two-dimensional echocardiography in the evaluation of congenital heart disease. It must be realized that currently, conventional Doppler methods and Doppler color flow imaging have added even more diagnostic power to cardiac ultrasound for evaluation of congenital heart disease. For many seemingly simple and some complex disorders, cardiac catheterization is no longer necessary when data can be reliably obtained by echo and Doppler methods. M-mode echocardiography has been almost totally supplanted by these newer modalities.

The purpose of this unit is to provide a *basic* understanding of congenital heart disease and how echocardiography is helpful in establishing diagnoses. As such, its aim is principally toward those with little background in this area. Not all disease entities can be covered and only the more common disorders will be described. Little discussion of patient management is possible.

All congenital heart disease is potentially complex. Such a statement should not be frightening as it only reflects the fact that the presence of one lesion increases the possibility for another. Multiple lesions are possible. For example, transposition of the great vessels may exist with or without ventricular septal defects or with or without right ventricular outflow tract obstruction. In addition, just like in adult acquired disease, congenital heart disorders represent a spectrum. There can be mild, moderate, or severe expressions of any disorder.

Views for Congenital Heart Disease

As with acquired heart disease, the standard apical, parasternal, and subcostal views are used for the majority of recordings. In addition, emphasis is placed on certain views that are particularly rewarding. For example, the subcostal approaches (Fig. 1) identify the interatrial septum and the relationships of the atrial and ventricular septum to the atrioventricular valves. Suprasternal views are good for examination of the great vessels and the aortic arch. All views obviously must be utilized. In small children, lack of attenuation from the rib cage permits routine imaging with high frequency transducers such as 5MHz or higher.



Fig. 1

Classification of Congenital Heart Disease

Many physicians dealing with adults find congenital heart disease extremely complex. The terms and classifications used over the years by pediatric cardiologists may be largely to blame. Most previous nomenclature systems are largely based upon embryology. Thus, such terms as L-loop and D-loop were common and generally confused most individuals. In this unit, a simple descriptive nomenclature, known as the sequential segmental approach, introduced during the 1980's is employed. It avoids terms derived from embryology and, where possible, uses simple and uncomplicated descriptions. Its major goal is to convey information simply and accurately without regard to how the lesions came to be.

The Sequential Segmental Approach

This newer nomenclature approach has remarkably simplified the classification of congenital heart disease. It is based on following the blood flow into the heart (systemic venous and pulmonary venous), through the heart (the atrioventricular valves and ventricles) and then out the great vessels (semilunar valves and great vessels). This nomenclature system is extraordinarily helpful to those conducting echocardiographic examinations as it forms a systematic guide for verification that all the pertinent chambers and valves and their relationships have been documented. The system is dependent on a few words that are very important in describing the various lesions:

Connection refers to the sequence of anatomic structures. Normally, the right atrium is connected to the right ventricle by means of the tricuspid valve. The right ventricle is then connected to the pulmonary artery by means of the pulmonic valve. Therefore, there are atrioventricular connections and ventriculo-great arterial connections.

Concordance describes the relationship between the various chambers, valves, and great vessels. In the normal heart all the connections and relationships in the anatomic sequence are concordant.

Discordance describes abnormal relationships between the various chambers and great vessels. For example, when the right atrium leads into the morphologic left ventricle and the left atrium into the morphologic right ventricle, the atrioventricular relationships are discordant, as seen in Fig. 2. Likewise, the atrioventricular relationships may be concordant (normal) but the ventriculo-great arterial relationships may be discordant where the aorta rises from the right ventricle and the pulmonary artery from the left ventricle. Known formerly as transposition of the great vessels, these abnormal relationships would now be termed ventriculo-great arterial discordance as seen in the right panel of Fig. 2.

Fig. 2

Absent or imperforate connections – Valves normally form the connections between chambers. There are atrioventricular connections that lead from the right atrium to right ventricle or left atrium to vessels. When connections are not present, the term *absent connection* is used. Thus, when the tricuspid valve is absent, an absent right atrioventricular connection may not be totally absent, only severely malformed and does not allow blood to pass antegradely. In this setting the term *imperforate connection* may be used, also seen in Fig. 3.

Fig. 3

Commitment further describes possible abnormalities of flow through valves into ventricles and great vessels. For example, in a patient with tetralogy of Fallot, the atria, atrioventricular valves, and ventricles are positioned normally, and concordant. Since the aorta overrides a ventricular septal defect the aorta is doubly committed to both ventricles. Likewise, in cases where there is only one ventricle (univentricular heart), both atrioventricular valves are usually *doubly committed* to the single ventricle.

Ambiguous is used when precise identification of a ventricle or other structure cannot be made. For example, in a univentricular heart with a doubly committed atrioventricular connection it may not be possible to always identify clearly whether it is the right or left ventricle. Thus, the single ventricle would be *ambiguous*.

Inlet refers to anomalies of the structures and flow into the ventricle.

Outlet refers to anomalies of the structures and flow out of the ventricles into the great vessels.

Classification of Congenital Heart Disease
The System in More Detail

The system assumes that flow through the heart is normal and begins with properly identifying the atria, and their position in the chest. In a normal individual there are two atria, each with venous inflow. One must identify the

inferior and superior vena cava inflows into the right atrium and, where possible, identify four pulmonary veins into the left atrium.

Following the normal sequence of flow, one then identifies the atrioventricular valves and ventricles. Normally there are two atrioventricular valves, tricuspid and mitral. The tricuspid valve is committed to the right ventricle and the mitral valve to the left ventricle. Normally both the atrial and ventricular septa are intact.

Again following the normal sequence of flow, blood should emerge out of the ventricles into the great vessels. The pulmonary artery, taking flow to the lungs, is normally committed to the right ventricle while the aorta, taking blood to the systemic circuit, is normally committed to the left ventricle.

The pulmonary artery emerges from the right ventricle and passes anterior to the aorta. The pulmonary artery then bifurcates and is differentiated from the aorta that forms an arch, giving off vessels to the head and neck. The pulmonary artery and aorta "criss-cross" as they arise from their respective ventricles.

Given these normal sequences and relationships the terms previously mentioned are used to describe abnormal hearts. Chambers, valves, or vessels may be absent (atretic) or small (hypoplastic). Relationships between chambers and valves may be concordant (normal) or discordant. In addition, chambers or valves may be doubly committed or normally committed. An outline of the disorders is presented in Table 1.

TABLE I
Outline of Congenital Heart Disorders Discussed in This Book

I. When chambers and valves are in normal sequence and position

A. When shunting is predominant
1. Atrial septal defects (secundum, primum, sinus venosus, and coronary sinus)
2. Ventricular septal defects (subarterial, muscular, inlet, and perimembranous)
3. Atrioventricular septal defects (AV canal defects)
4. Patent ductus arteriosus

B. When stenosis or obstruction is predominant
1. Absent atrioventricular connections (tricuspid and mitral atresia)
2. Absent or obstructed ventriculo-great arterial connections (pulmonary atresia, aortic)
3. Obstructed great arteries (coarctation of the aorta, aortic atresia)
4. Obstructed venous inflow (total anomalous pulmonary venous return)

C. Anomalous valve position (Ebsteins's anomaly)

II. When chambers and valves are not in normal sequence or relationship

A. Anomalies of relationships between atria and ventricles
1. Double-inlet or right ventricle (with univentricular heart)
2. Atrioventricular discordance (corrected transposition)

B. Anomalies or relationships between ventricles and great vessels
1. Tetralogy of Fallot
2. Double-outlet right and left ventricles
3. Truncus arteriosus
4. Ventriculo-great arterial discordance (transposition of the great vessels)

When Chambers and Valves Are Not in Normal Sequence or Relationship
Anomalies of the Relationships Between the Ventricles and Great Vessels

These anomalies may also be quite confusing and it is important to recognize that mastering and understanding the abnormal morphology is dependent on determining which ventricle is committed to which great vessel. Proper echocardiographic technique requires the examiner to trace the great vessels distally in all cases to determine which vessel bifurcates (the pulmonary artery) and which great vessel gives rise to an arch (the aorta). Then the examiner traces backward to determine to which ventricle each great vessel connects.

Such malformations are comprised of many entities. Among them are: tetralogy of Fallot, double-outlet right ventricle, double-outlet left ventricle, ventriculo-great arterial discordance (or transposition of the great vessels), and truncus arteriosus. Except for transposition of the great vessels, these lesions require that a subarterial ventricular septal defect be present.

Tetralogy of Fallot

In Fallot's tetralogy, the aorta overrides the septum (Fig. 34). The aorta is, therefore, doubly committed to both ventricles to a variable degree. By definition, however, the aorta is committed to the left ventricle by at least 50 percent.



Fig.34

A narrowed right ventricular outflow tract is also seen. If a pulmonary valve is seen, pulmonary atresia is excluded, but in severe tetralogy this valve may easily be lost in the mass of echoes arising from the hypertrophied outflow tract.



Fig.35

Fig. 35 shows a subcostal view of the right ventricle and right ventricular outflow tract in a patient suspected of having tetralogy of Fallot. The aorta arises partly from the right ventricle, and the right ventricular outflow trace is severely narrowed by both the infundibular septum (between the aorta and pulmonary artery) and thickening on the free wall of the right ventricle. In this patient, the areas of narrowing essentially formed two chambers, one below and one above the area of narrowing to form a "double-chambered right ventricle". While such discrete narrowing is uncommon, such an image does help to understand the location of obstruction in these patients.

Surgical correction of this anomaly requires closure of the ventricular septal defect. The mass of anomalous muscle in the right ventricular outflow tract must also be removed, and the right ventricular outflow tract opened, by placing a patch graft on the outer wall of the right ventricular outflow tract.

When Chambers and Valves Are Not in Normal Sequence or Relationship
Anomalies of the Relationship Between Atria and Ventricles

Double-outlet ventricle

Double-outlet right ventricle may be thought of as a severe form of tetralogy of Fallot, except for the fact that most, if not all, of the aorta is committed to the right ventricle (Fig. 36). In this setting oxygenated blood crosses from the left ventricle to the aorta across the subarterial ventricular septal defect. Right ventricular outflow tract obstruction may or may not be present. The pulmonary artery also arises from the right ventricle.

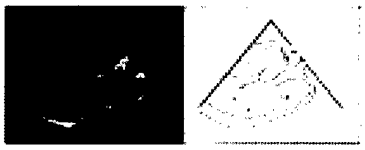

Fig.36

Clinically, double-outlet right ventricle can mimic several other lesions. With pulmonary stenosis, an anterior pulmonary artery, and overriding of the aorta, the clinical findings indicate tetralogy of Fallot. Indeed, the dividing line between the two lesions can be difficult to determine. Absence of fibrous continuity between the mitral and posterior semilunar valves, once thought to be the definitive feature of the condition is only sometimes present.

The relationship of the great vessels may be normal or reversed. Fig. 37 shows a subcostal view of a double-outlet right ventricle where the aorta and the pulmonary artery are reversed. Here, the aorta is anterior to the pulmonary artery. Less commonly encountered is a double- outlet left ventricle where both great vessels emerge from the left ventricle. A ventricular septal defect is usually seen in this entity.



Fig.37

When Chambers and Valves Are Not in Normal Sequence or Relationship
Anomalies of the Relationships Between the Ventricles and Great Vessels

Truncus arteriosus

Truncus arteriosus is a general diagnostic term used when there is a common origin of the pulmonary artery and aorta from the ventricles. A ventricular septal defect is present. Thus, both ventricles have a single outlet. Blood flow to the lungs is supplied from any number of possibilities: the main pulmonary artery may arise directly from the aorta, main stem pulmonary arteries may arise from the sides or back of the aorta, or pulmonary blood flow is supplied only by collaterals. Obviously, prognosis in the latter case is dismal.

The echocardiographic features of persistent truncus arteriosus are remarkably similar to those of Fallot's tetralogy despite the marked clinical differences between the two lesions. Absence of the right ventricular outflow tract and pulmonary valve are the essential features. It may also be possible to identify pulmonary arteries arising from the truncus, if present.

When Chambers and Valves Are Not in Normal Sequence or Relationship
Anomalies of the Relationships Between the Ventricles and Great Vessels

Ventriculo-great arterial discordance

This entity is also known as transposition of the great vessels. In pure transposition, there are two atria, two atrioventricular valves and two ventricles – all positioned normally. The pulmonary artery, however, arises from the left ventricle and the aorta (with coronary arteries) arises from the right ventricle (Fig. 2). If there is no arterial or ventricular septal defect, the venous blood returns to the heart and immediately passes through the right ventricle into the aorta without passing through the lungs. Likewise, the oxygenated blood returns to the left atrium and transits through the left ventricle to the pulmonary artery and back into the lungs.

Thus, venous and systemic circuits are entirely separate rather than in tandem. This situation is incompatible with life. In such a critical situation, a balloon-tipped catheter is passed across the atrial septum from right to left. The balloon is then inflated and pulled back across the atrial septum creating a large atrial septal defect where venous and oxygenated blood can mix. Although such a measure does not correct the problem, it can be life-saving until more definitive correction can be performed. In the presence of an atrial and/or ventricular septal defect, such emergent measures are usually not required.

The echocardiographic diagnosis of ventriculo-great arterial discordance is dependent on proper identification of the great vessels and their commitments. Fig. 38 shows a parasternal long axis with the aortic arch seen arising from the

Fig.38

anterior ventricle (right) and the pulmonary artery (characterized by its bifurcation) arising from the posterior ventricle (left).

A modified parasternal short axis is shown in Fig. 39 where the pulmonary bifurcation in the posterior great vessel is readily recognized.

Fig. 40 shows inverted (but anatomically correct) images from the subcostal area in an infant with transposition. Posterior angulation of the transducer shows the left ventricle to connect to the pulmonary artery while anterior angulation shows the right ventricle to connect to the aorta.



Fig.39

Surgical correction of ventriculo-great arterial discordance is based on restoration of the proper sequence of blood flow. The atrial septum may be surgically removed and complex baffles may be placed in the atria that redirect flow. The baffles allow returning venous flow to pass through the mitral valve into the left ventricle and out the pulmonary artery to the lungs. Returning oxygenated blood then passes on another side of the baffles through the tricuspid valve into the right ventricle and out the aorta. Such an "atrial switch" is known as a Mustard or Senning procedure. The long-term problem with such procedures is that the right ventricle is forced to perform at systemic pressures for many years, resulting in dilatation and, ultimately, failure in many patients.



Fig.40

More recently, success has been achieved with a great arterial switch where the pulmonary artery and aorta are sectioned just above the valvular levels and surgically reconnected to the proper ventricles. The coronary arteries are also moved from the anterior great vessel to the newly created aorta. The advantage of this operation is that it recommits the proper ventricle to the proper circuit. The disadvantage is that the initial operative risk is higher since the very small coronary arteries must be manually moved and reimplanted without jeopardizing coronary blood flow.

Ventriculo-great arterial discordance may also occur with right ventricular outflow tract obstruction. The presence of such obstruction complicates patient management and surgical correction.

One unusual disease of the coronary arteries, Kawasaki disease, results in inflammatory changes of the coronaries that cause dilatation of the vessels, or localized aneurysm formation and thrombosis. Such coronary abnormalities may be detected with two- dimensional echocardiography. Fig. 41 shows serial short axes of the left main and left anterior descending coronary arteries with marked dilatation.

Fig.41

APPENDIX E. Slides Used for Course "Anatomic Basis of Echocardiography"



3-Dimensional Orientation of the Human Heart

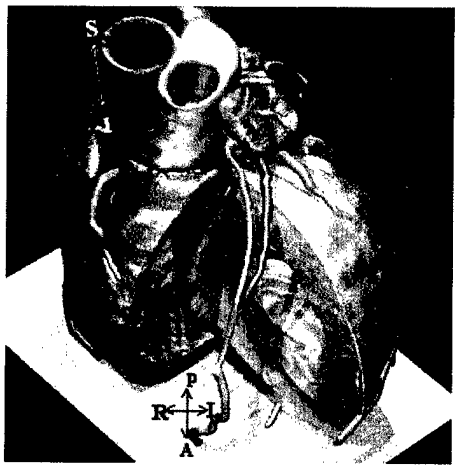

Cross Sectional Planes of the Heart

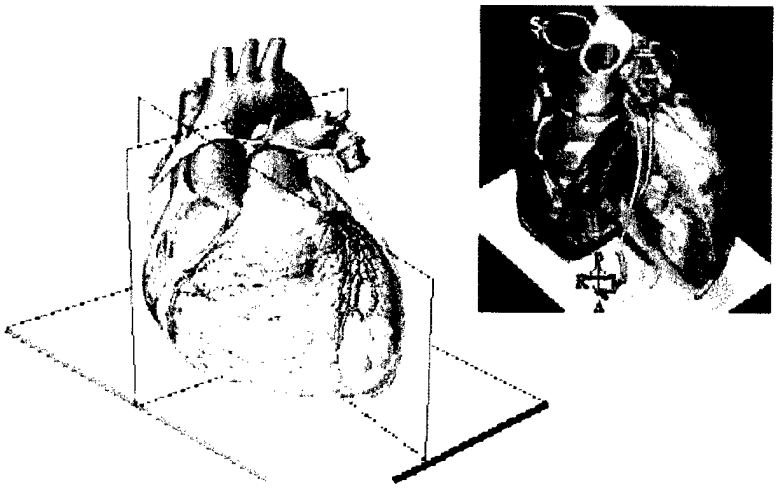

Anatomically Correct Display

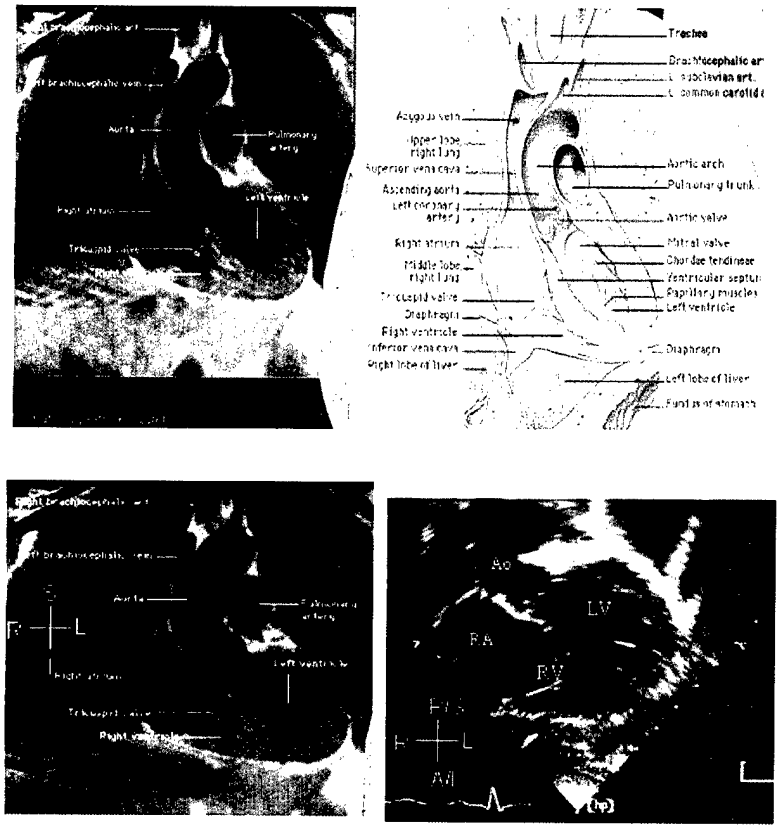

A comparison between a MRI scan in the coronal plane with an echocardiogram in the sub-xiphoid long-axis view. Anatomically correct display of structures allows a better orientation at all times while perfoming an echocardiogram

Anatomically Correct Display

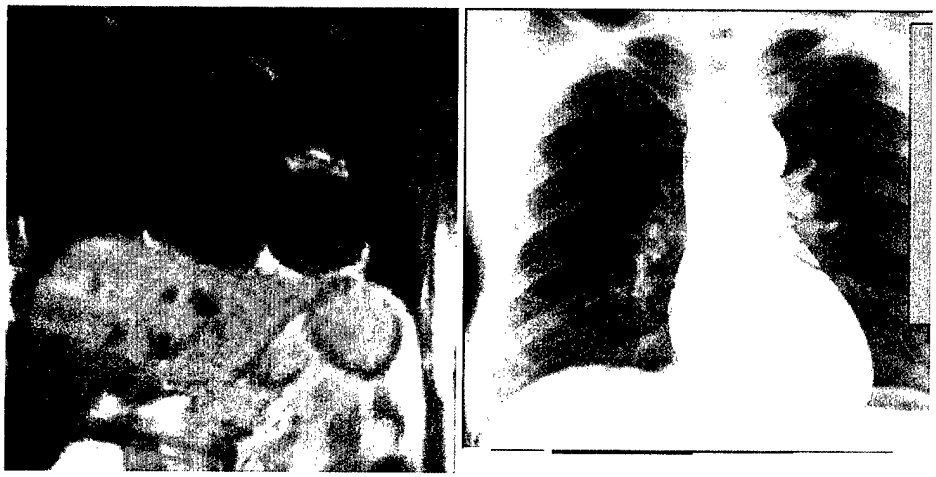

The Window for Trans-Thoracic Echocardiography

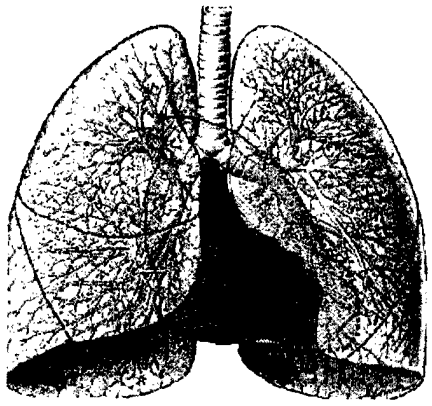

The window available for transthoracic echocardiography is limited by lung tissue that surrounds it.

Transducer Positions: Levocardia

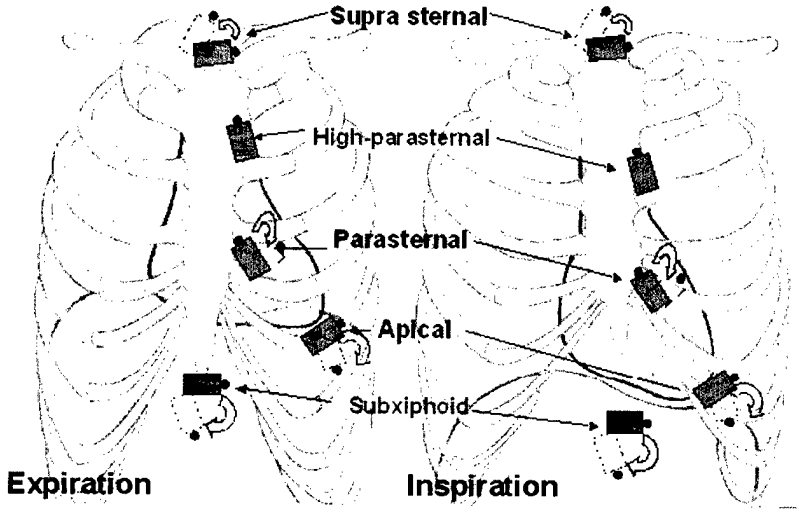

Transducer Positions:Dextrocardia

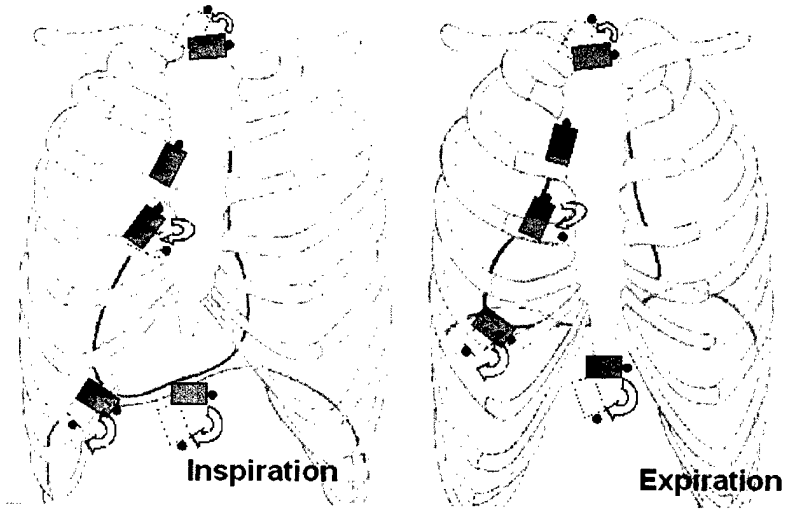

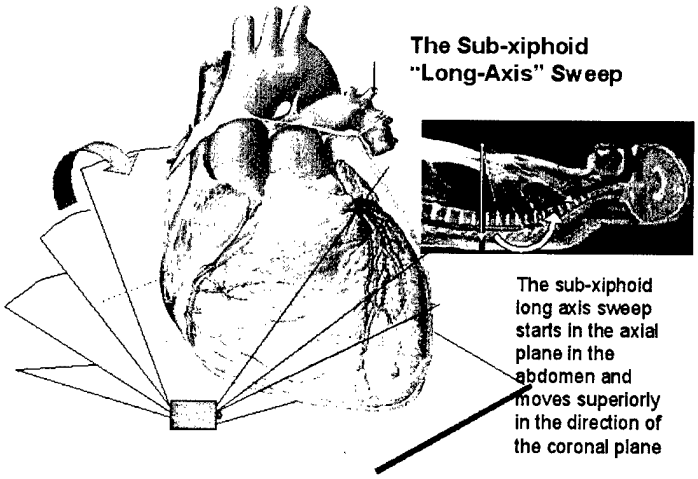

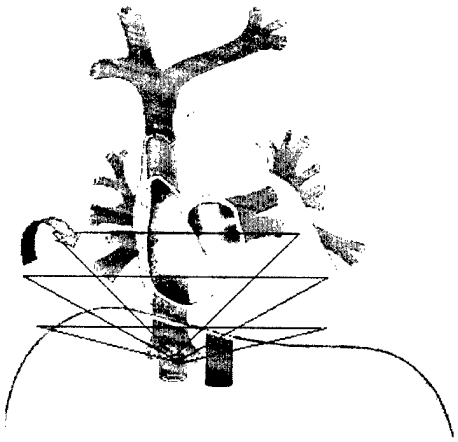

The first structures to be seen in the sub-xiphoid long axis sweep are the IVC and the hepatic veins along with the aorta. The side-side relationship of the IVC and the abdominal aorta is first identified and the IVC/hepatic veins are traced to the heart

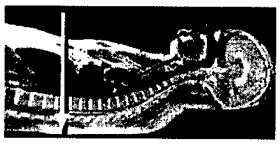

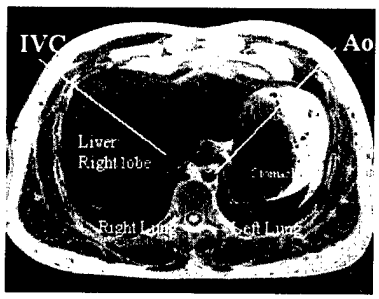

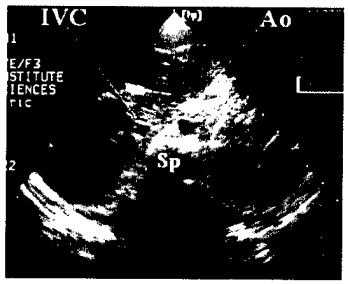

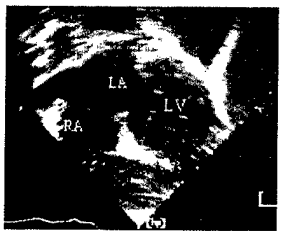

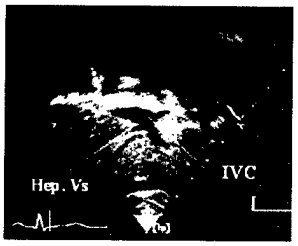

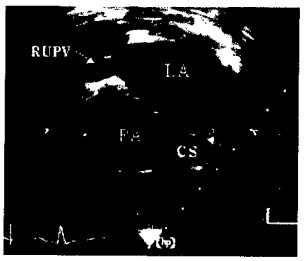

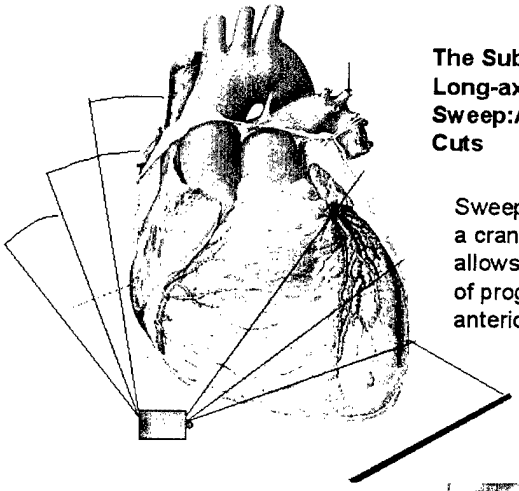

The Sub-xiphoid Long-axis Sweep:Anterior Cuts

Sweeping further in a cranial direction allows visualization of progressively anterior structures

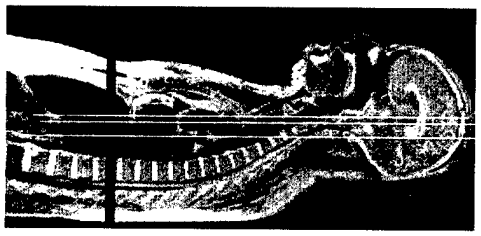

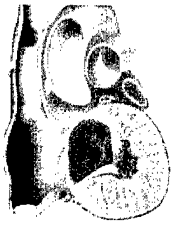

These are three cuts in the coronal plane. These views cannot be recreated by transthoracic echo echocardiography and ideally require MRI.

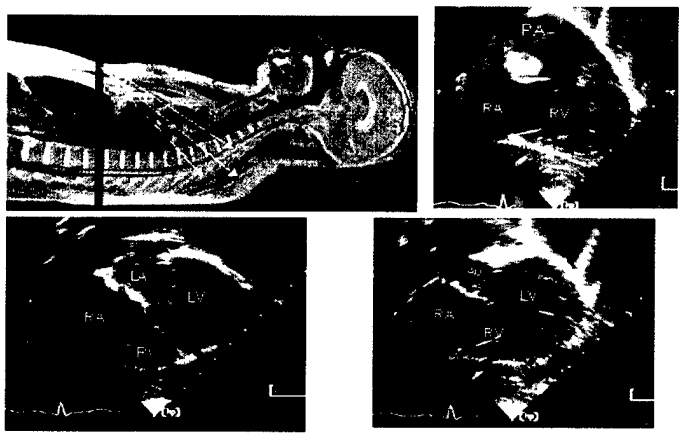

By sweeping cranially, progressively anterior structures are visualized

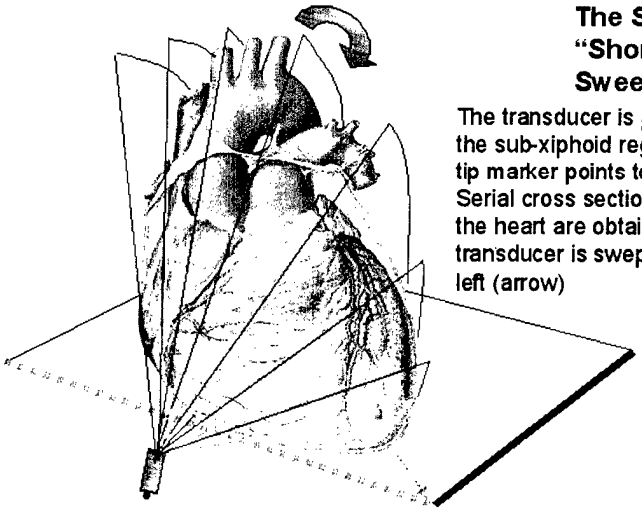

The Subxiphoid "Short –Axis" Sweep

The transducer is positioned in the sub-xiphoid region and the tip marker points to the feet. Serial cross sectional views of the heart are obtained as the transducer is swept from right to left (arrow)

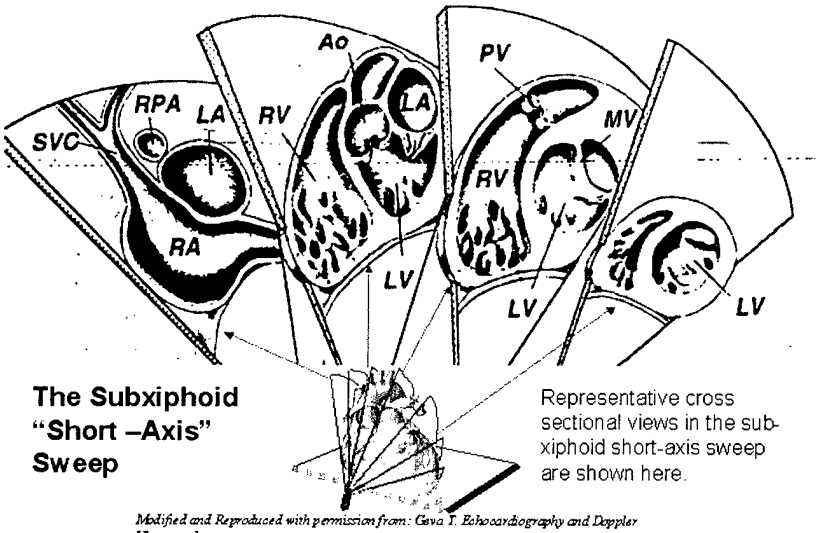

The Subxiphoid "Short –Axis" Sweep

Representative cross sectional views in the sub-xiphoid short-axis sweep are shown here.

Modified and Reproduced with permission from: Geva T. Echocardiography and Doppler Ultrasound.
In: Garson A Jr, Bricker JT, Fisher DJ, Neish SR (editors). The Science and Practice of Pediatric Cardiology. Baltimore, MD: Williams & Wilkins; 1997; 789-843

Subxiphoid short-axis sweep: echo-anatomy correlations

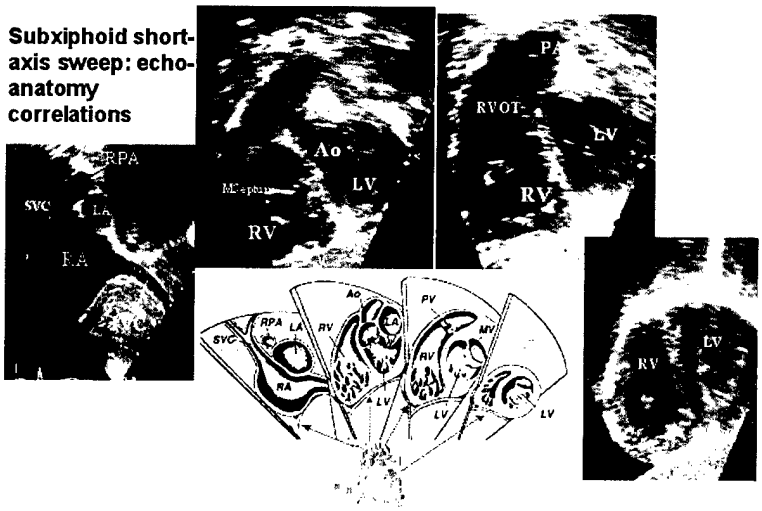

Atrial Septum: Subxiphoid Views

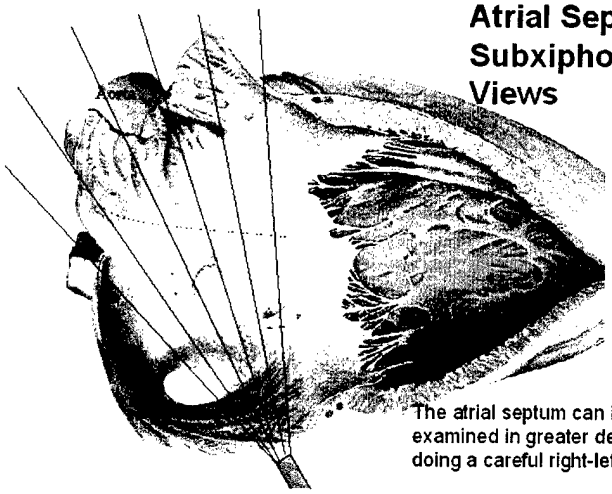

The atrial septum can be examined in greater detail by doing a careful right-left sweep

Atrial Septal Evaluation

Right septum

←: Rt upper pulm vein

Mid-septum

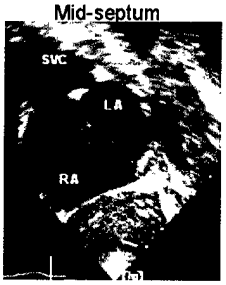

Left septum

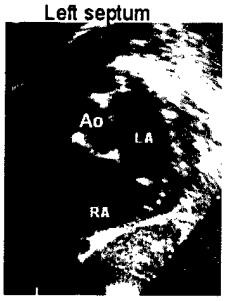



Subxiphoid Short-axis Sweep: Ventricular Septum



Cross Section of the Ventricles Below Mitral Valve Apparatus

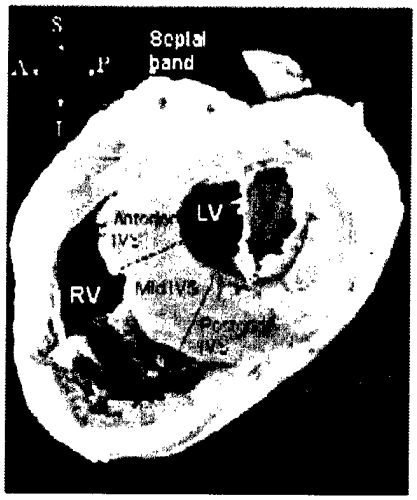



Subxiphoid Short-axis Sweep of the : Ventricular Septum

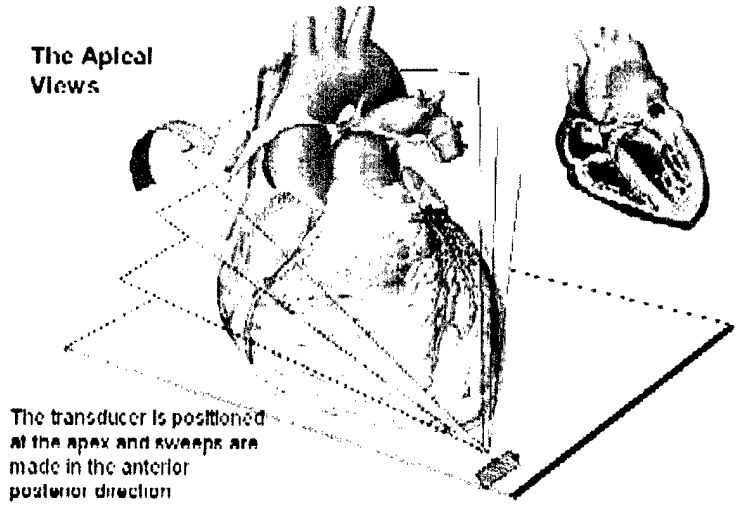

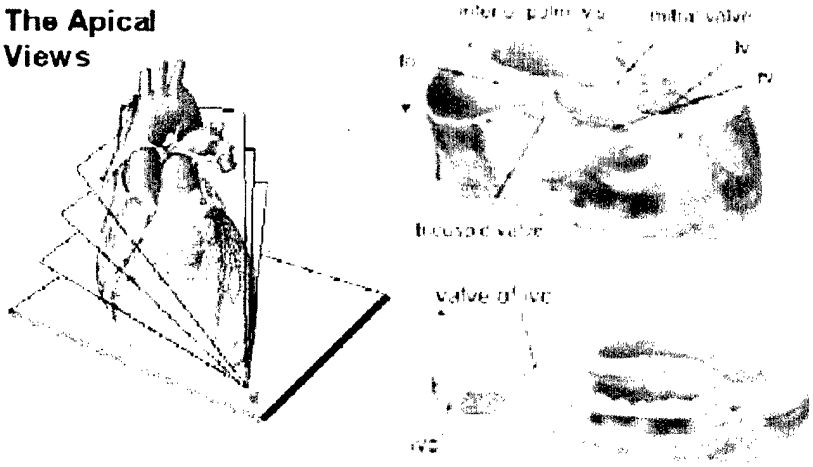

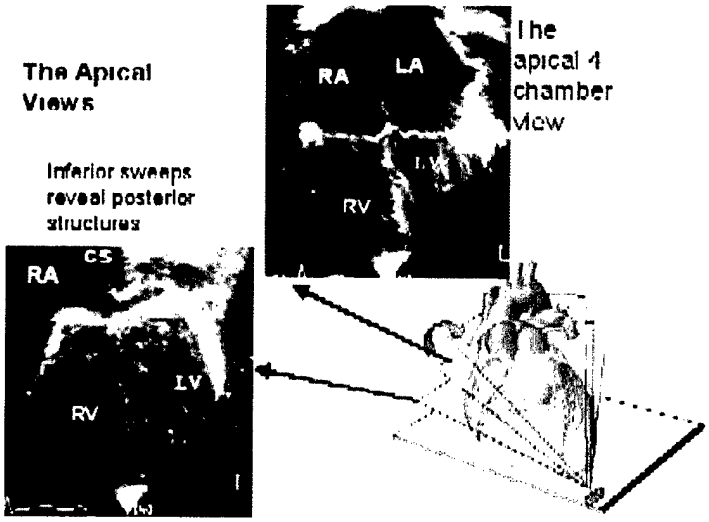

The apical 4 chamber view

The Apical Views: Anterior Cuts

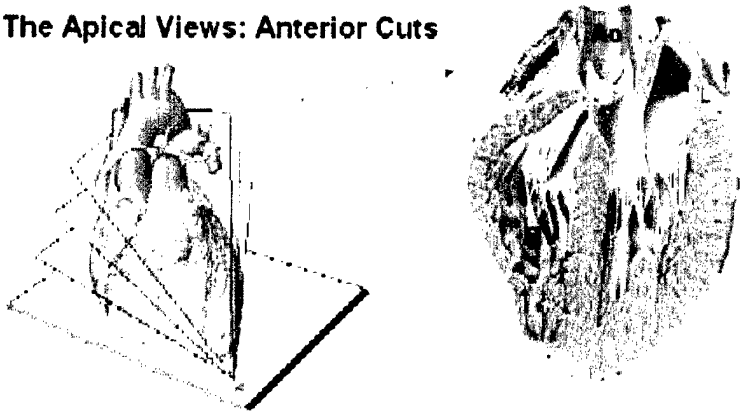

Sweeping superiorly allows examination of progressively anterior structures.

The Apical "5 Chamber" View

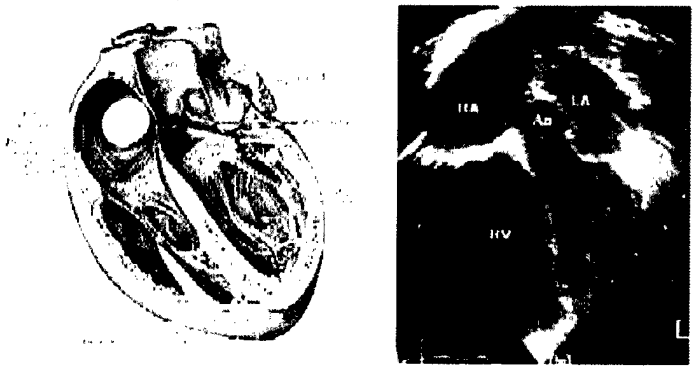

The echo-anatomy correlations in the apical view (anterior sections) obtained by sweeping superiorly are shown here

The Apical Long Axial Views

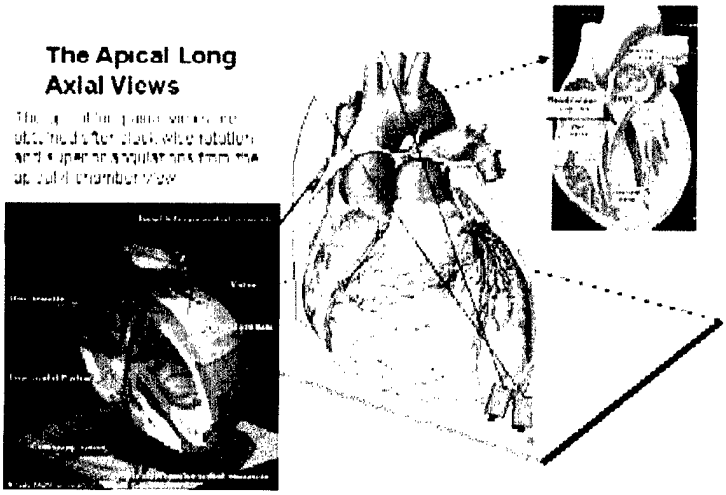

The Apical Long Axial Views

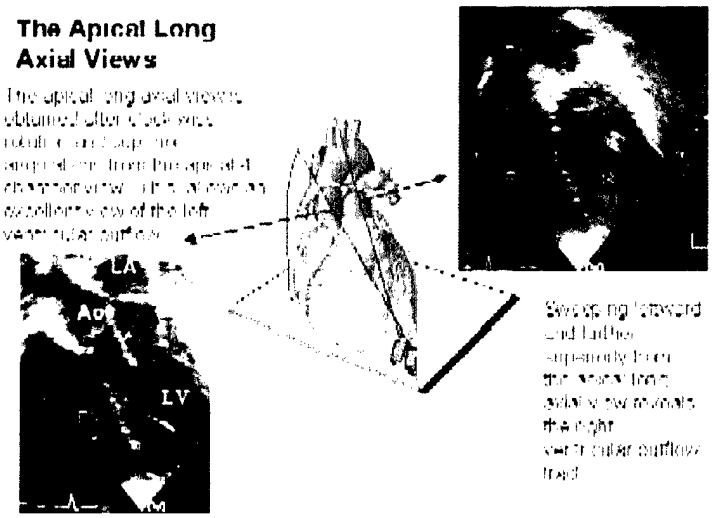

The Parasternal Long –Axis Sweep

By sweeping rightwards and inferiorly the tricuspid valve and the adjacent RV inflow is seen

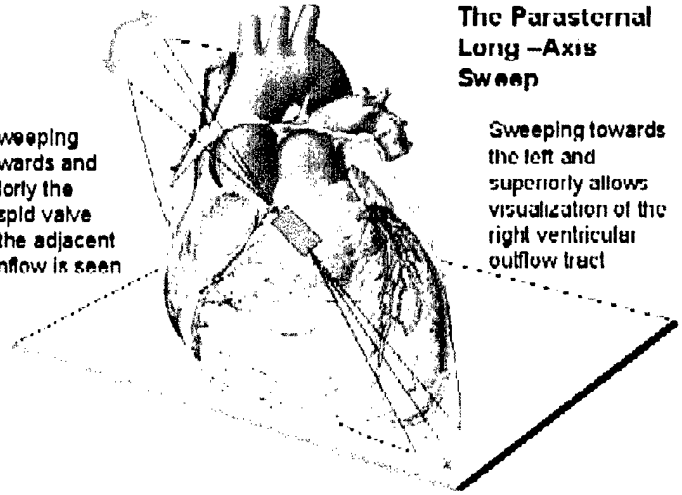

Sweeping towards the left and superiorly allows visualization of the right ventricular outflow tract

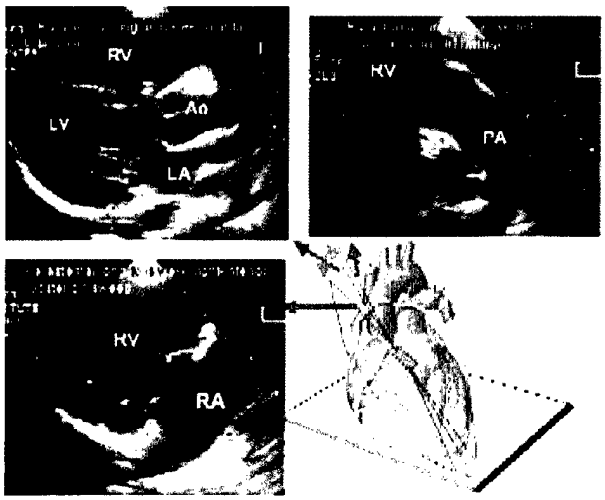

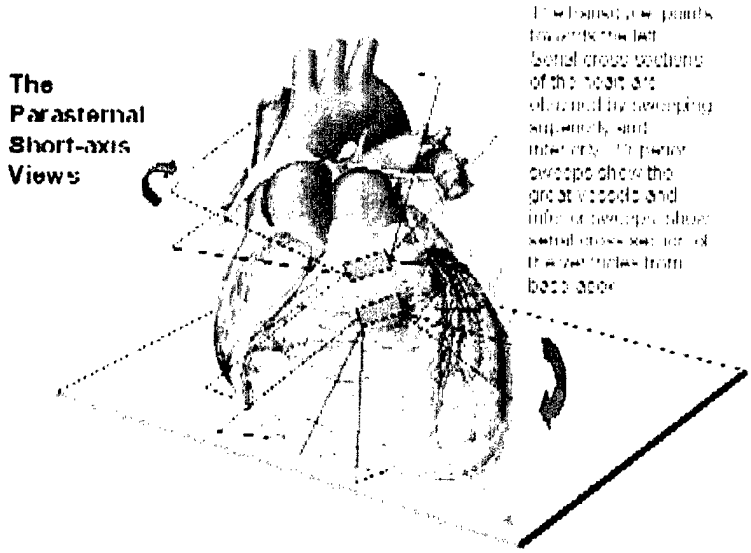
The
Parasternal
Short-axis
Views

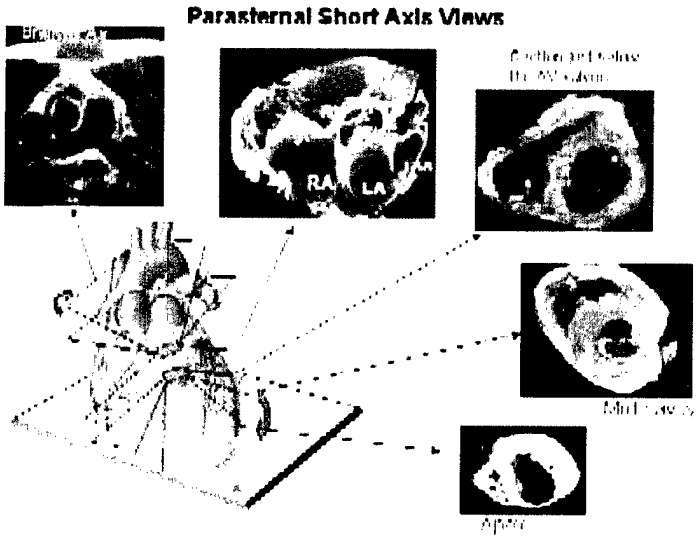
Parasternal Short Axis Views
RA
LA
Apex

APPENDIX F. Sample Data Entry Pages for DOD Infant Heart Study

Update Subject follow-up - 3066

Initial Encounter - Follow-up

Follow-up for: 3066

Click here for instructions on using this form.

Follow up Outcome Data: Initial Admission

Tertiary care hospital	ICU Days	Ward bed days	Nursery bed days
childil	9	9	0
Outreach hospital	**ICU Days**	**Ward bed days**	**Nursery bed days**
Silver Cross Hospital	1	0	0
Transport to tertiary		**Date**	
Air ☐ Land ☐ None ☐		12/21/1999	

Cath (date)		primary diagnosis (one only)	None
		you selected:	
	(Hold control (CTRL) key down and click to make multiple selections)		Anomalous left coronary artery Anomalous pulmonary venous return - partial Anomalous pulmonary venous return - total cardiac Anomalous pulmonary venous return - total infradiaphragmatic Anomalous pulmonary venous return - total supracardiac Aortic arch anomalies - coarctation of the aorta
Interventional Cath	☐ yes	☐ no Describe if yes	
Surgical (date)	10/22/1999	primary diagnosis (one only)	Transposition of the great arteries - D-TGA
		you selected:	**Aortic arch anomalies - coarctation of the aorta, Atrial septal defect - patent foramen ovale, Atrial septal defect - secundum, Single ventricle**

		secondary diagnosis (you may select more than one):	Anomalous left coronary artery Anomalous pulmonary venous return - partial Anomalous pulmonary venous return - total cardiac Anomalous pulmonary venous return - total infradiaphragmatic Anomalous pulmonary venous return - total supracardiac Aortic arch anomalies - coarctation of the aorta
		You selected:	**Norwood operation, stage 1**
		Type of surgery	Arterial switch operation ASD repair Atrial Septectomy AV canal repair Balloon atrial septostomy Coarctation repair
		Discharge date: 01/08/2000	

Outpatient follow-up tertiary care hospital:

Cardiology/CV surgery visits scheduled. 2

Clinic visits:

	Yes No		Yes No		Yes No		Yes No
Physical Therapy		Occupational Therapy		Genetics		Audiology	
Nutrition		Neurology		ENT		Renal	
Speech Therapy		Other					

No transport:

Outreach hospital

Outreach ICU days	0	Outreach ward days	0	Nursery bed days	0

Outpatient F/U at outreach hospital:

Cardiology/CV surgery visits scheduled. 0

Other outreach visits

Physical therapy		Occupational Therapy		Genetics		Audiology	
Nutrition		Neurology		ENT		Renal	

Speech Therapy	☐ ☐	Other	☐ ☐				

Please take a moment to review your input before submitting. At this point you may want to print this page for your files. Thank you.

Submit

SFU edit page

Update Control follow-up - 4056 Edit Page

Initial Encounter - Follow-up

Enter patient id: 4056

Click here for instructions on using this form.

Follow up Outcome Data: Initial Admission

Tertiary care hospital	ICU Days	Ward bed days	Nursery bed days
childil	7	0	0
Outreach hospital	**ICU Days**	**Ward bed days**	**Nursery bed days**
Lake Forest Hospital	1	0	0
Transport to tertiary		**Date**	
Air ☐ Land ☐ None ☐		12/17/1999	

Cath (date)		primary diagnosis (one only)	
		you selected:	
	(Hold control (CTRL) key down and click to make multiple selections)		Anomalous left coronary artery Anomalous pulmonary venous return - partial Anomalous pulmonary venous return - total cardiac Anomalous pulmonary venous return - total infradiaphragmatic Anomalous pulmonary venous return - total supracardiac Aortic arch anomalies - coarctation of the aorta
Interventional Cath	☐ yes	☐ no Describe if yes	
Surgical (date)		primary diagnosis (one only)	
		you selected:	

		secondary diagnosis (you may select more than one):	Anomalous left coronary artery Anomalous pulmonary venous return - partial Anomalous pulmonary venous return - total cardiac Anomalous pulmonary venous return - total infradiaphragmatic Anomalous pulmonary venous return - total supracardiac Aortic arch anomalies - coarctation of the aorta
		You selected:	
		Type of surgery:	Arterial switch operation ASD repair Atrial Septectomy AV canal repair Balloon atrial septostomy Coarctation repair
		Discharge date: 12/23/1999	

Outpatient follow-up tertiary care hospital:

Cardiology/CV surgery visits scheduled. 1

Clinic visits:

	Yes No		Yes No		Yes No		Yes No
Physical Therapy		Occupational Therapy		Genetics		Audiology	
Nutrition		Neurology		ENT		Renal	
Speech Therapy		Other					

No transport:

Outreach hospital

Outreach ICU days	0	Outreach ward days	0	Nursery bed days	0

Outpatient F/U at outreach hospital:

Cardiology/CV surgery visits scheduled. 0

Other outreach visits

Physical therapy		Occupational Therapy		Genetics		Audiology	
Nutrition		Neurology		ENT		Renal	

Speech Therapy	☐ ☐	Other	☐ ☐				

Please take a moment to review your input before submitting. At this point you may want to print this page for your files. Thank you.

Submit Reset

CFU edit page

Update Subject - 13

Section A. Transmission Data

Date of echocardiogram 07/01/1999			
	days	hours	minutes
Time from first phone call to echo interpretation days:		2	31
Transmission time (minutes)	31		
To change select correct button	Type:	Emergent	Elective

If elapsed time is greater than or equal to 3 hours please explain:

Referring site:	evanston	Referring Physician:	michael capla		
Tertiary care site:	childil	Distance from referring site (in miles)	13	Distance from referring site(in minutes)	45

Section B. Patient Demographics

DOB	06/29/1999	Time of Birth	6:48				
Ht (cm)	43.0	Weight (kg)	2.6	or Ht (inches)		Weight (ounces)	
	Gender	M	F	Gestational age (weeks)	39		
Ventilated		Not ventilated		Referred by fetal echocardiogram	Yes / No		

Section C. Diagnosis and transfer

Pre transmission diagnosis (reason for echo)
(select one only)

R/o congenital heart disease

Non Cardiac Diagnosis
You may select more than one by holding the control (Ctrl) key and clicking with the mouse pointer
You selected the following:

CNS
GI
GU
Multiple congenital anomalies
Musculo Skeletal
Respiratory

If you selected a non cardiac diagnosis please indicate if it is significant or minor

Diagnosis	Significant	Minor	None	Diagnosis	Significant	Minor	None
CNS	☐	☐	☐	GI	☐	☐	☐
GU value selected	☐	☐	☐	Multiple congenital anomalies value selected	☐	☐	☐
Musculoskeletal value selected	☐	☐	☐	Respiratory value selected	☐	☐	☐
Syndrome value selected	☐	☐	☐				

Post transmission diagnosis (based on transmitted image only)
Primary (select one only)

Ventricular septal defect - muscular

Secondary (may select more than one)
You selected the following: Atrial septal defect - patent foramen ovale, Patent ductus arteriosus, Pulmonary artery - pulmonary hypertension

Anomalous left coronary artery
Anomalous pulmonary venous return - partial
Anomalous pulmonary venous return - total cardiac
Anomalous pulmonary venous return - total infradiaphragmatic
Anomalous pulmonary venous return - total supracardiac
Aortic arch anomalies - coarctation of the aorta

Final diagnosis (after original videotape reviewed; note any differences from transmitted study)
Primary (select one only)

Ventricular septal defect - muscular

Secondary (may select more than one)
You selected the following: Atrial septal defect - patent foramen ovale, Patent ductus arteriosus, Pulmonary artery - pulmonary hypertension

Anomalous left coronary artery
Anomalous pulmonary venous return - partial
Anomalous pulmonary venous return - total cardiac
Anomalous pulmonary venous return - total infradiaphragmatic
Anomalous pulmonary venous return - total supracardiac
Aortic arch anomalies - coarctation of the aorta

If patient transferred, final diagnosis at referral site after repeat echo or additional testing (e.g. catheterization)
Primary (select one only)

Secondary (may select more than one)
You selected the following:

Anomalous left coronary artery
Anomalous pulmonary venous return - partial
Anomalous pulmonary venous return - total cardiac
Anomalous pulmonary venous return - total infradiaphragmatic
Anomalous pulmonary venous return - total supracardiac
Aortic arch anomalies - coarctation of the aorta

Recommended follow-up after transmission
You selected the following:

Patient transferred ☐ Recommended inpt f/u ☐ Outpt f/u ☐ No further f/u ☐

Section D. Transmission issues

You selected the following:

Audio	☐	Video	☐		
Telecommunication lines	☐	Could not transmit	☐	Other	☐

Section E. Medical Outcomes

Medical outcomes

Death
Cardiac arrest
IVH
Indocin

Please take a moment to review your input before submitting. Thank you. At this point you may want to print this page for your files.

Update Subject

Edit Page